RADIAL TECHNIQUES, TIPS AND TRICKS FOR SUCCESS

Jennifer A Tremmel, MD, MS

Stanford University Medical Center

And for my next trick…

WOMEN'S HEARTHEALTH at STANFORD

- I don't really have any new tips or tricks…
  - Using 7F Slender for cases needing more back-up
  - Balloon-assisted tracking to get up the arm
  - Having patients take a deep breath to get around the arch
  - Using a universal guide (such as Ikari Left) for STEMI or multi-vessel PCI
  - Adding a guide extension if you need more support
- Focus instead on newer techniques for preventing RAO
  - Including distal radial access

Stanford MEDICINE

Reducing RAO

- Best practice goal: <5% (current rate 7.7%)
- Conventional techniques for prevention:
  - Minimizing sheath size
  - Anticoagulation (≥75 IU/kg)
  - Limiting compression duration (≤120 minutes)
  - Patent hemostasis
- Variations on the theme:
  - Use of hemostatic discs or patches (to reduce time and/or level of compression)
  - Simultaneous ulnar compression (increasing radial flow)
- Alternate access: distal radial
- Treatment: ulnar compression; 1-4 weeks of LMWH

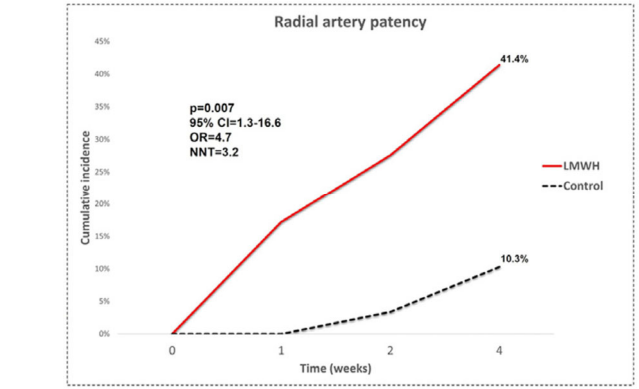

- Also evidence for subQ nitro pre-procedure and IA nitro pre-hemostasis

Bernat et al. J Am Coll Cardiol Intv 2019;12:2235–46; Didagelos et al. J Am Coll Cardol Intv 2022;15;1686-87
Rashid et al. J Am Heart Assoc 2016;5:e002686; Safirstein et al. J Am Coll Cardiol 2022;15:810-819

PROTHECT Trial

WOMEN'S HEARTHEALTH at STANFORD

- Randomized 1,469 patients (diagnostic and PCI) to:
  - **Patent hemostasis (PH):** band removed at 2 hours
  - **Ulnar compression method (UM)** with patent hemostasis: ulnar removed at 1 hour; radial 2 hours later
  - **Hemostatic disc (HD)** or patch along with pneumatic compression: 8ml air, removed 3ml 20 minutes later and 5ml after another 20 minutes, band removed at 1 hour
- Radial patency was assessed at 24 hours by plethysmography; in the event of RAO, it was confirmed by ultrasound and reassessed at 30 days
- 93% right radial artery; 47.4% diagnostic and 52.6% PCI

Eid-Lidt et al. J Am Coll Cardiol Intv 2022;15:1022–1029

Stanford MEDICINE

PROTHECT Trial

- Overall rate of RAO 4.6% with no significant difference between the groups

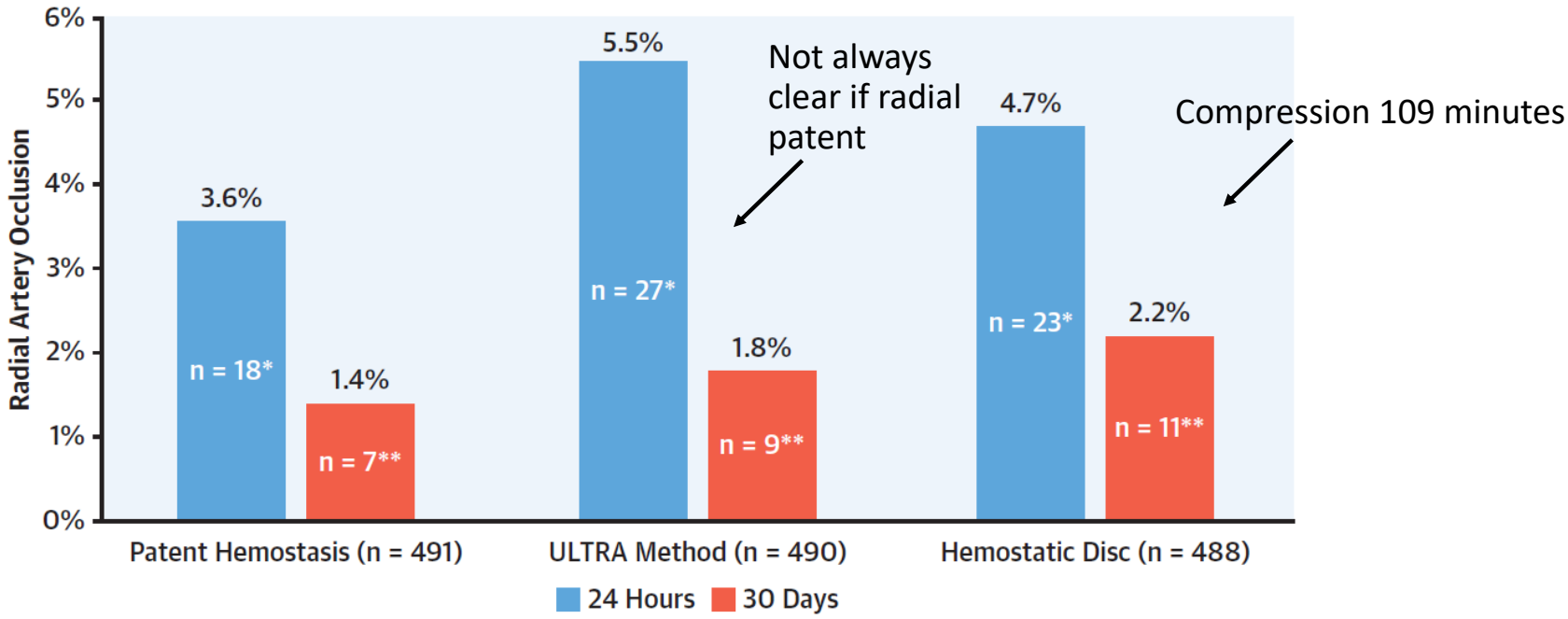

Eid-Lidt et al. J Am Coll Cardiol Intv 2022;15:1022–1029

Distal Radial Access (DRA)

WOMEN'S HEARTHEALTH at STANFORD

- Got a reputation as a "gimmick" because of early rise through social media
- However, data have been coming and they're intriguing…
- *Potential real* benefits:
  - Reduced forearm RAO
  - Left radial artery use while mitigating forearm radial injury (bypass conduits, A-V fistulas)
  - Increased comfort for operator and patient (particularly with left radial access)
  - Quicker hemostasis time
  - Absence of venous compression causing venous stasis
- At this point, there are observational data that *any* coronary procedure can be done via the DRA

Stanford MEDICINE

DRA vs. TRA

- In general, observational and 2 single-center RCTs have shown
  - Less forearm RAO
  - Less spasm
  - Less hemostasis time
  - More crossover
  - Longer access and procedural times
  - Potentially more radiation

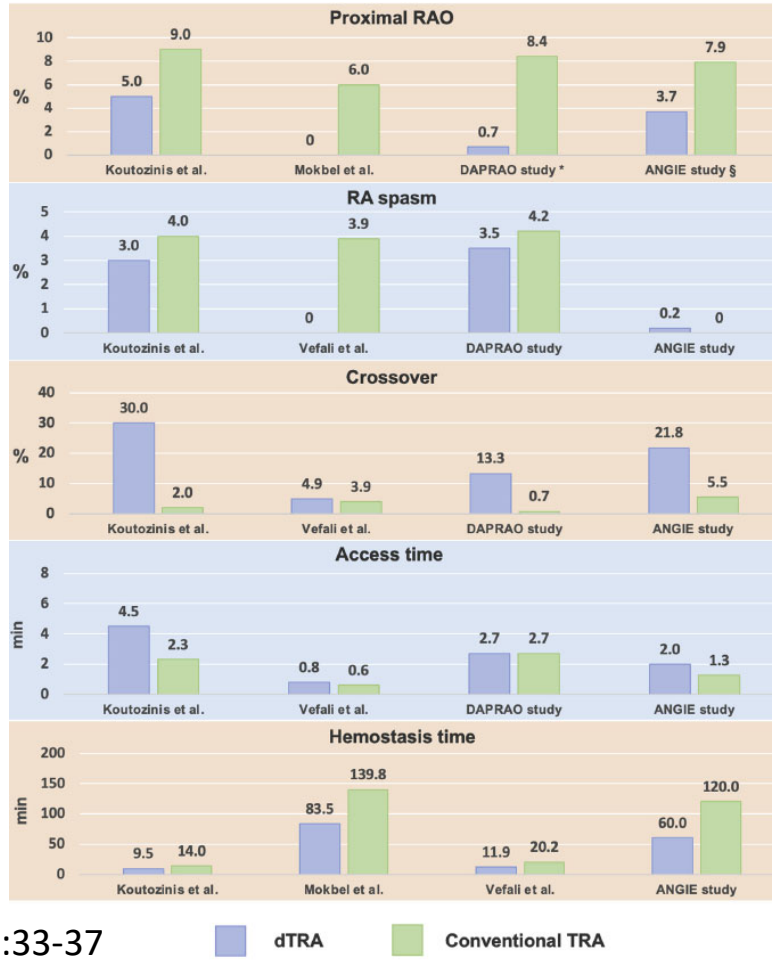

Valgimigli et al. J Am Coll Cardiol Interv 2022;15:33-37

DISCO RADIAL Trial

WOMEN'S HEARTHEALTH at STANFORD

- Multi-center trial of 1,307 patients randomized to conventional TRA vs. DRA
- Operators were experienced with radial and had to have done at least 100 distal radial procedures
- Cases were diagnostic or PCI (no STEMI or CTO)
- Right or left radial was left up to the operator, as was use of ultrasound
- 6Fr Glidesheath Slender was used in all patients regardless of access
- 5000 heparin with ACT of 250-300 secs
- Conventional radial used patent hemostasis; DRA was per practice
- Primary endpoint was forearm RAO, as assessed by duplex ultrasound

Aminian et al. J Am Coll Cardiol Intv 2022;15:1191–1201

Stanford MEDICINE

DISCO RADIAL Trial

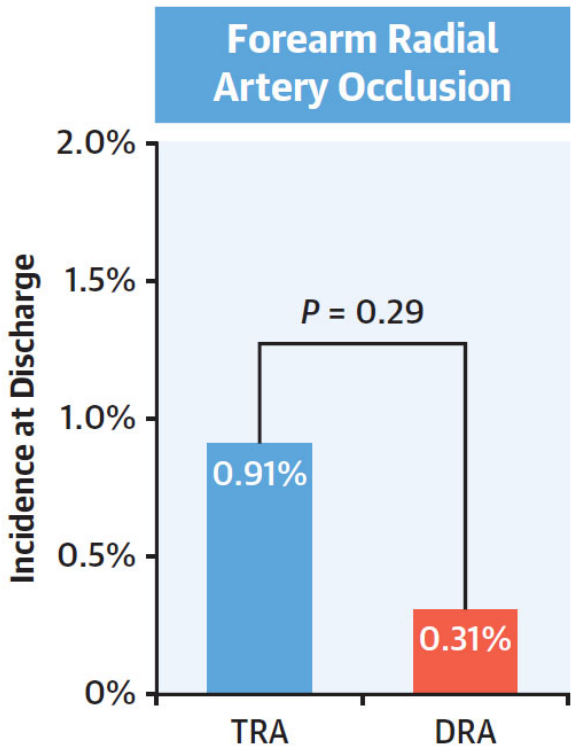

- RAO was not significantly different, but was incredibly low in both groups (note that they did use mostly best practices)
- Fairly high rate of cross-over (usually to ipsilateral forearm radial) and more spasm in DRA
- Shorter hemostasis time with DRA and similarly low rate of vascular complications (4.1% TRA vs. 6.0% DRA

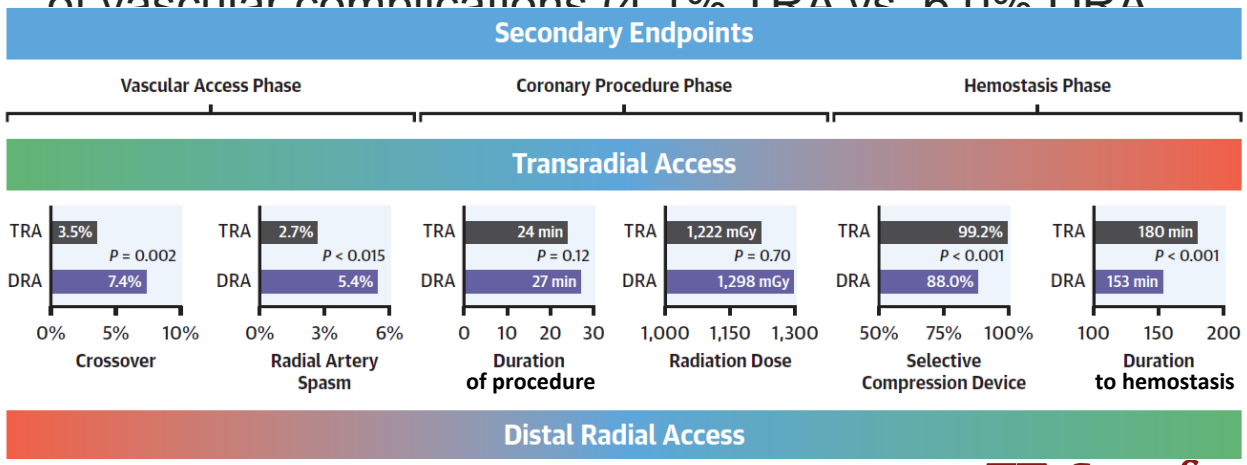

Aminian et al. J Am Coll Cardiol Intv 2022;15:1191–1201

Anatomy—it's the same artery continuing on

- Distal to the superficial palmar arch, allowing for antegrade forearm radial flow, which might minimize RAO (at the wrist)
- Occlusion does not reduce flow in the forearm radial artery
- Superficial to fascial compartments
- Superficial course and bone
- 2 places to access:
  - Snuffbox (most common)
  - Dorsum of the hand

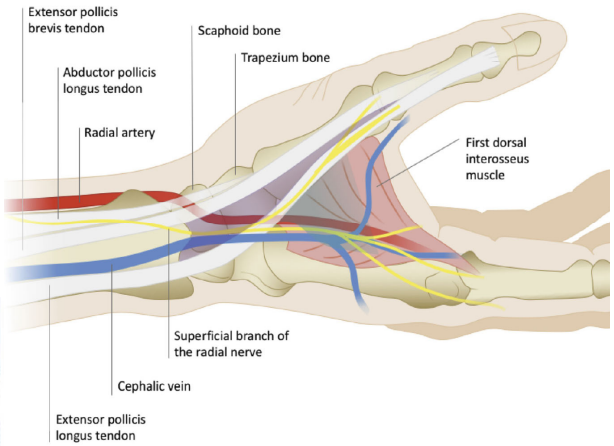

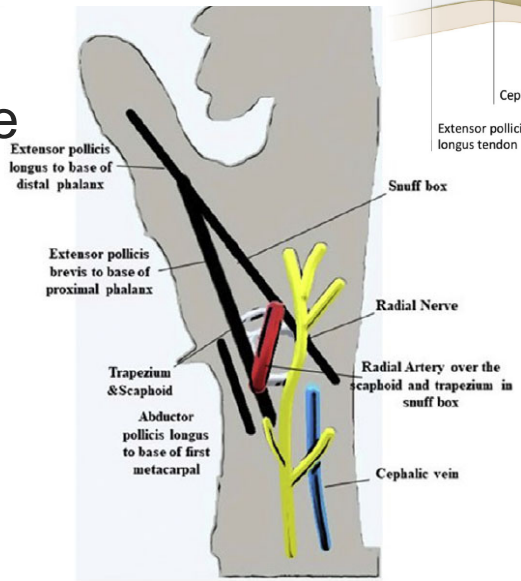

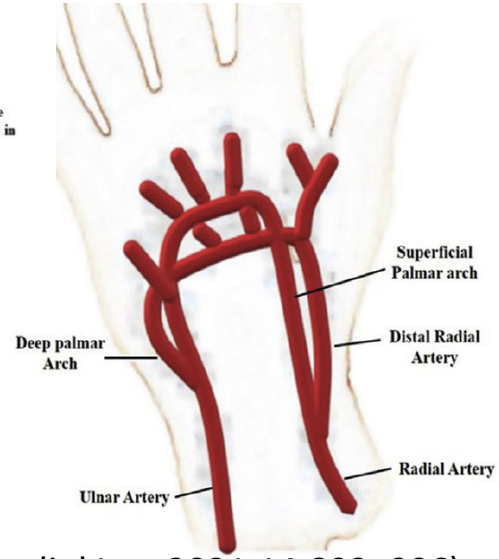

Sgueglia et al. J Am Coll Cardiol Intv 2021;14:892–906)

Set-up and access

WOMEN'S HEARTHEALTH at STANFORD

RDRA

LDRA

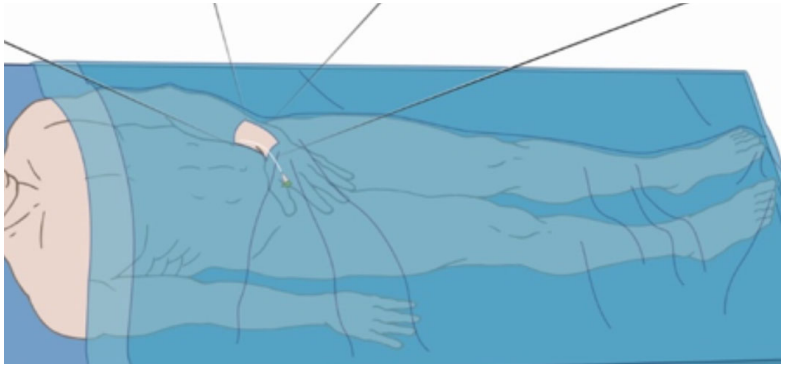

- Use ultrasound
- Slightly smaller than at forearm (~0.5mm)
- Artery takes a curvilinear route
- Thumb adduction may help straighten the artery
- Can use anterior wall or through-and-through puncture

Stanford MEDICINE

Hemostasis

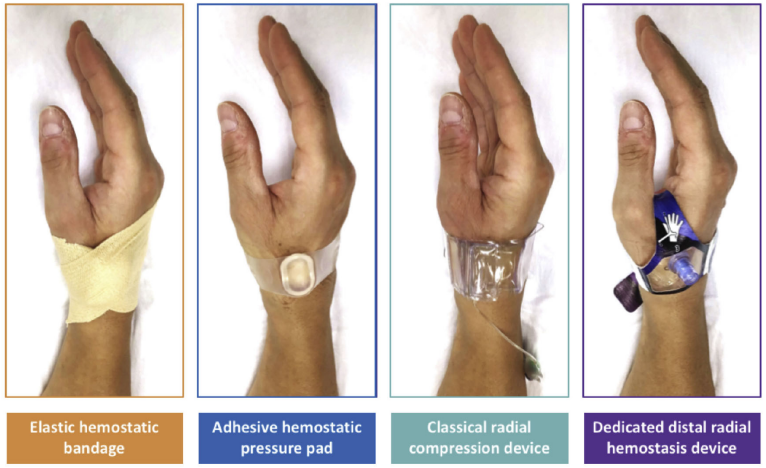

- There are no randomized studies comparing the safety and efficacy of the different hemostatic methods
- Assessing patency of the distal radial artery is difficult and whether it needs to be done is not known
- The distal radial artery in the anatomic snuffbox sits in a groove that limits compression; this may not be the case for the radial artery at the dorsum of the hand
- Reported vascular complications are rare (no actual reports of bone ischemia)

Learning curve

WOMEN'S HEARTHEALTH at STANFORD

- Just as with conventional TRA, there's a learning curve so you can certainly try a few to see what it's like, but if you plan to incorporate it into your regular practice, you need to devote the same effort that you did with conventional TRA
- It's a new set-up and hemostasis regimen, so you need to get staff trained and on board
- There will be failures in the beginning that will lessen, so be ready for frustration
- Start with easy cases
- Reasonably to use 30-50 cases as an average learning curve

Stanford MEDICINE

Conclusions

WOMEN'S HEARTHEALTH at STANFORD

- Prevention of RAO remains important, particularly now that the radial approach is a Class 1A guideline for PCI
- Continue to focus on the basics
  - Minimizing sheath size (Slender sheaths)
  - Proper anticoagulation
  - Limiting compression time
  - Patent hemostasis
- Keep abreast of emerging ways to improve your practice
  - Ipsilateral ulnar compression
  - Hemostatic patches
  - Using LMWH for treatment of RAO
  - Distal radial access (appreciate that there is a learning curve)

Stanford MEDICINE