

IVUS & OCT Image Interpretation Made Easy

Evan Shlofmitz, DO, FACC

Director of Intravascular Imaging

**St. Francis Hospital
Roslyn, New York**

Disclosures:



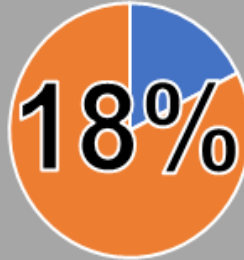


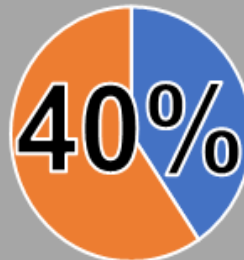
Affiliation/Financial Relationship

- Consultant
- Speakers' Bureau
- Advisory Board
- Other

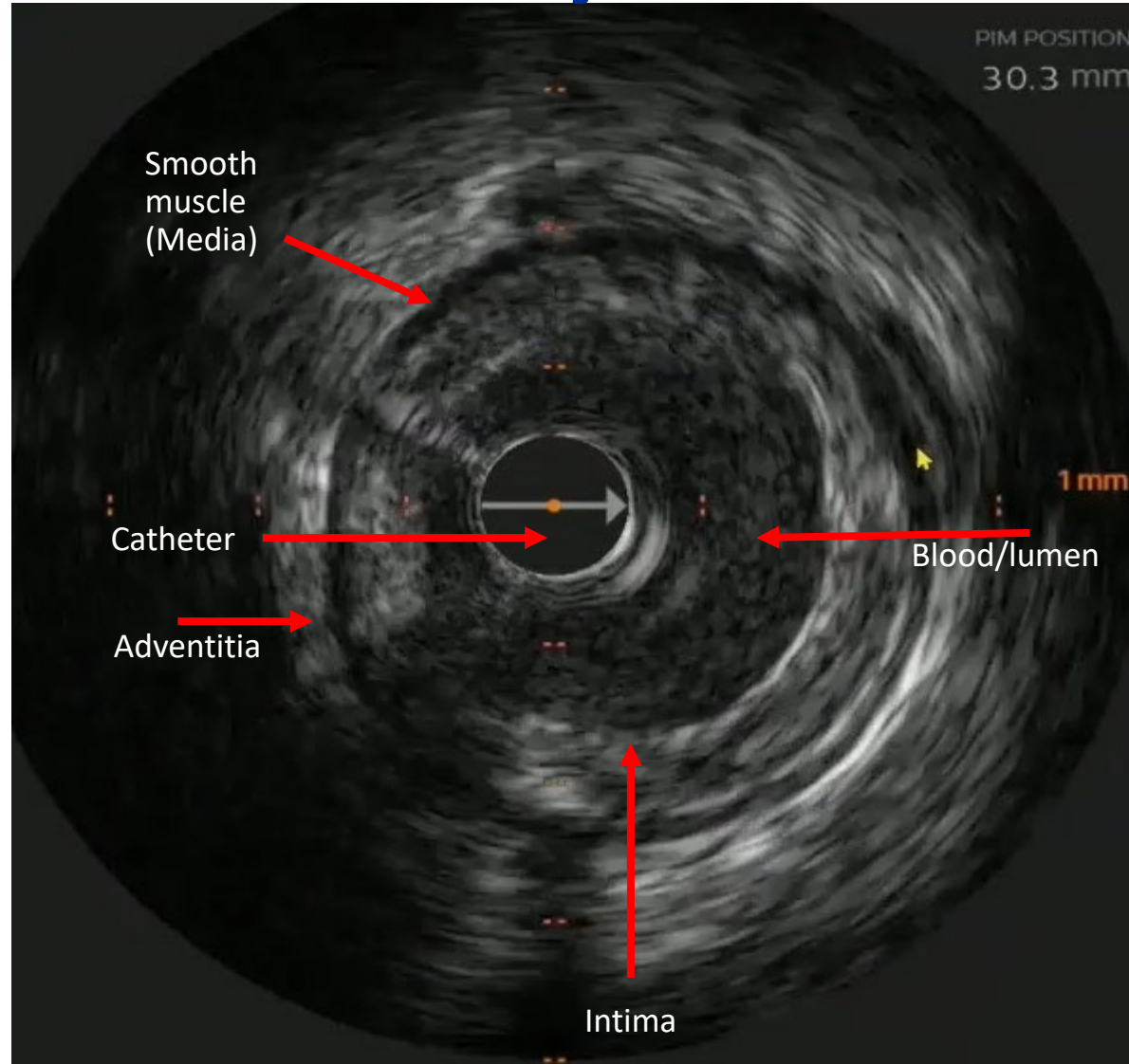
Company

- Abbott Vascular, ACIST Medical, Boston Scientific, Philips, Shockwave Medical, Terumo
- Amgen, AstraZeneca, Janssen Pharmaceuticals, Novo Nordisk
- Abbott Vascular, ACIST Medical, AstraZeneca, Boston Scientific, Philips, RadiAction, Xenter
- Co-Director, Optimizing PCI (OPCI)

Interventional Cardiology Fellows-in-Training self-reported training outcomes in intravascular imaging and physiology

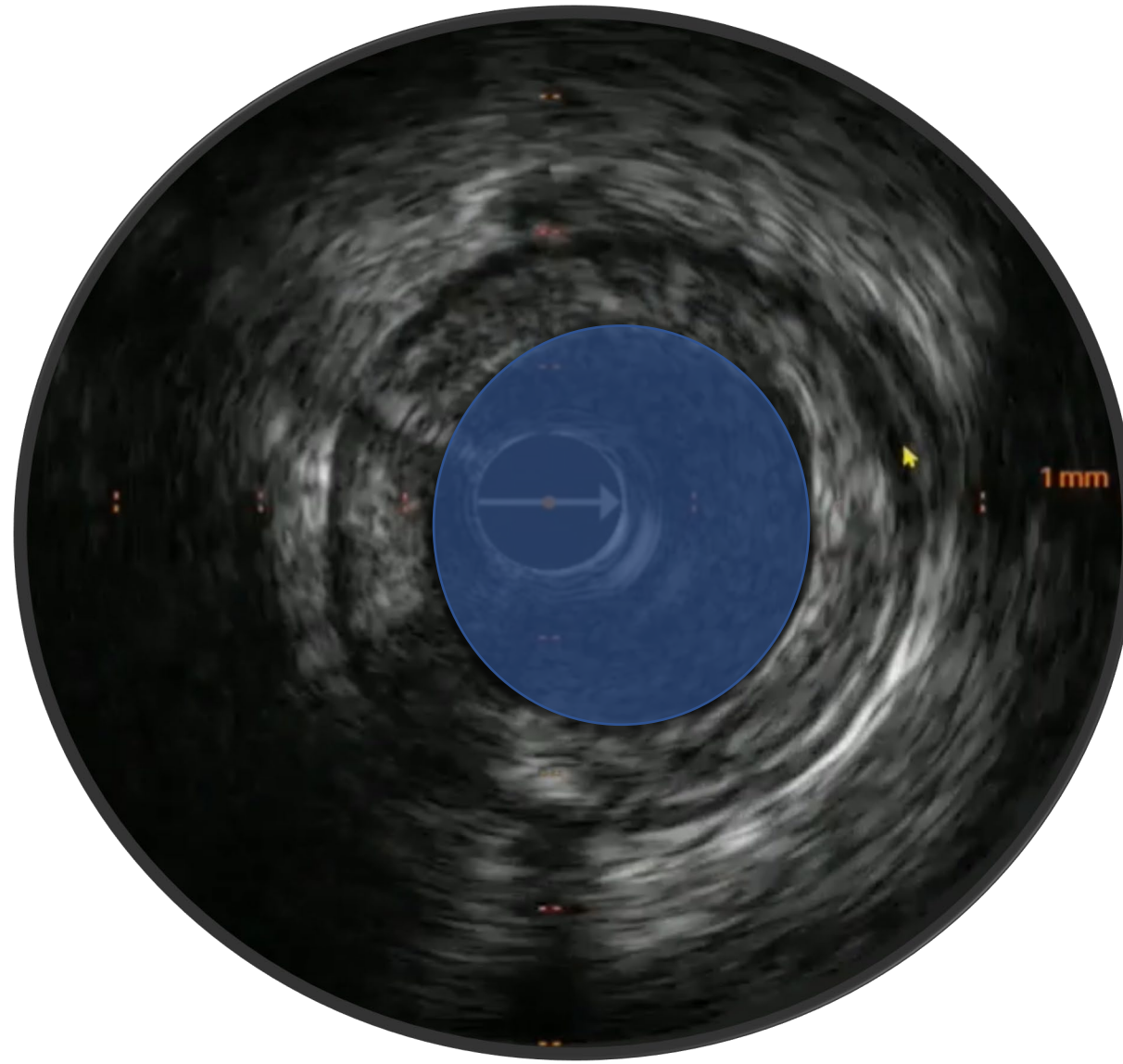
Competency-based independence in...			Yes	No
Physiology	Intravascular Ultrasound (IVUS)	Optical Coherence Tomography (OCT)		
				
All modalities	At least one modality	No modalities		
				

Identify the basics

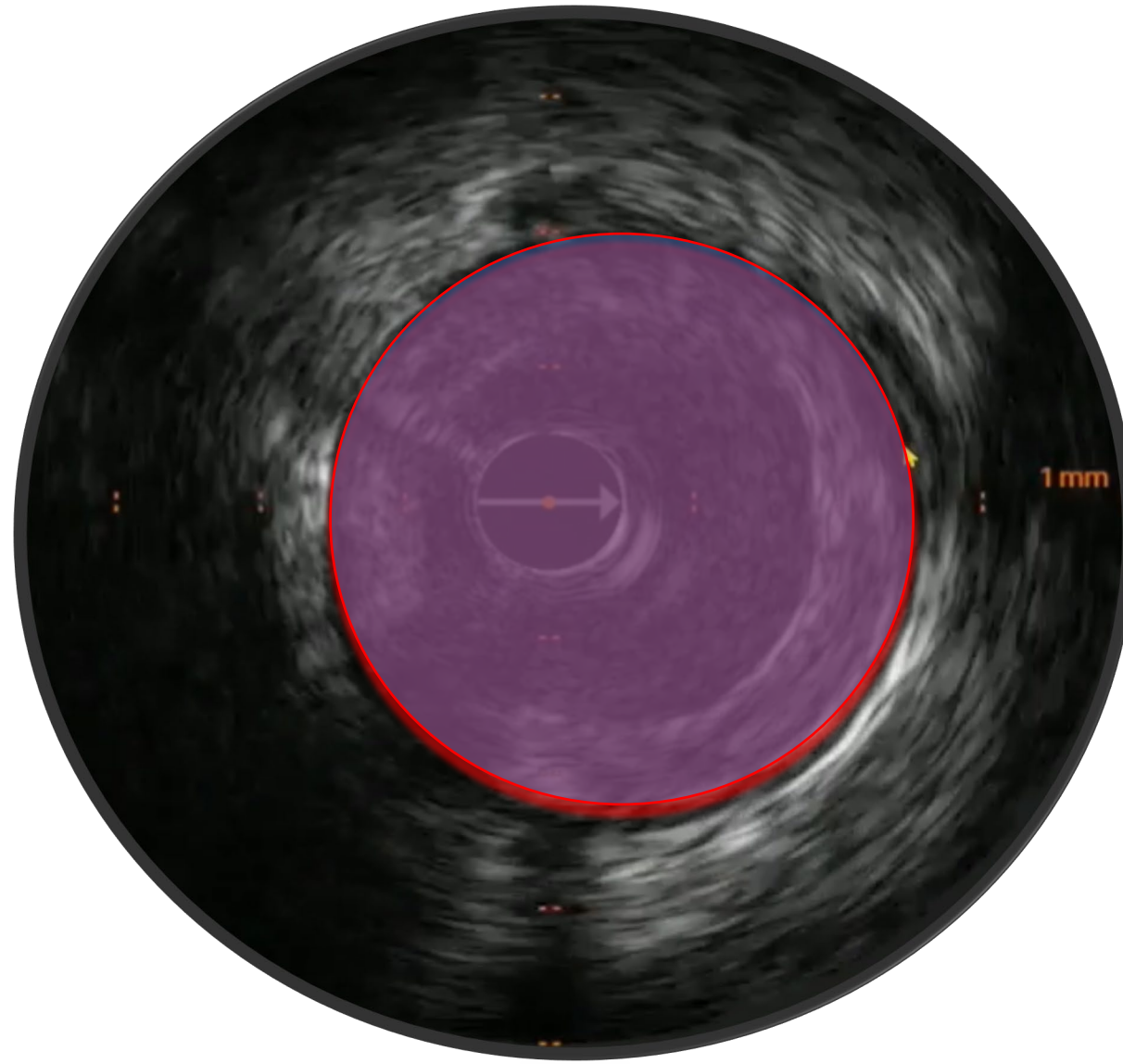


Master the Measurements

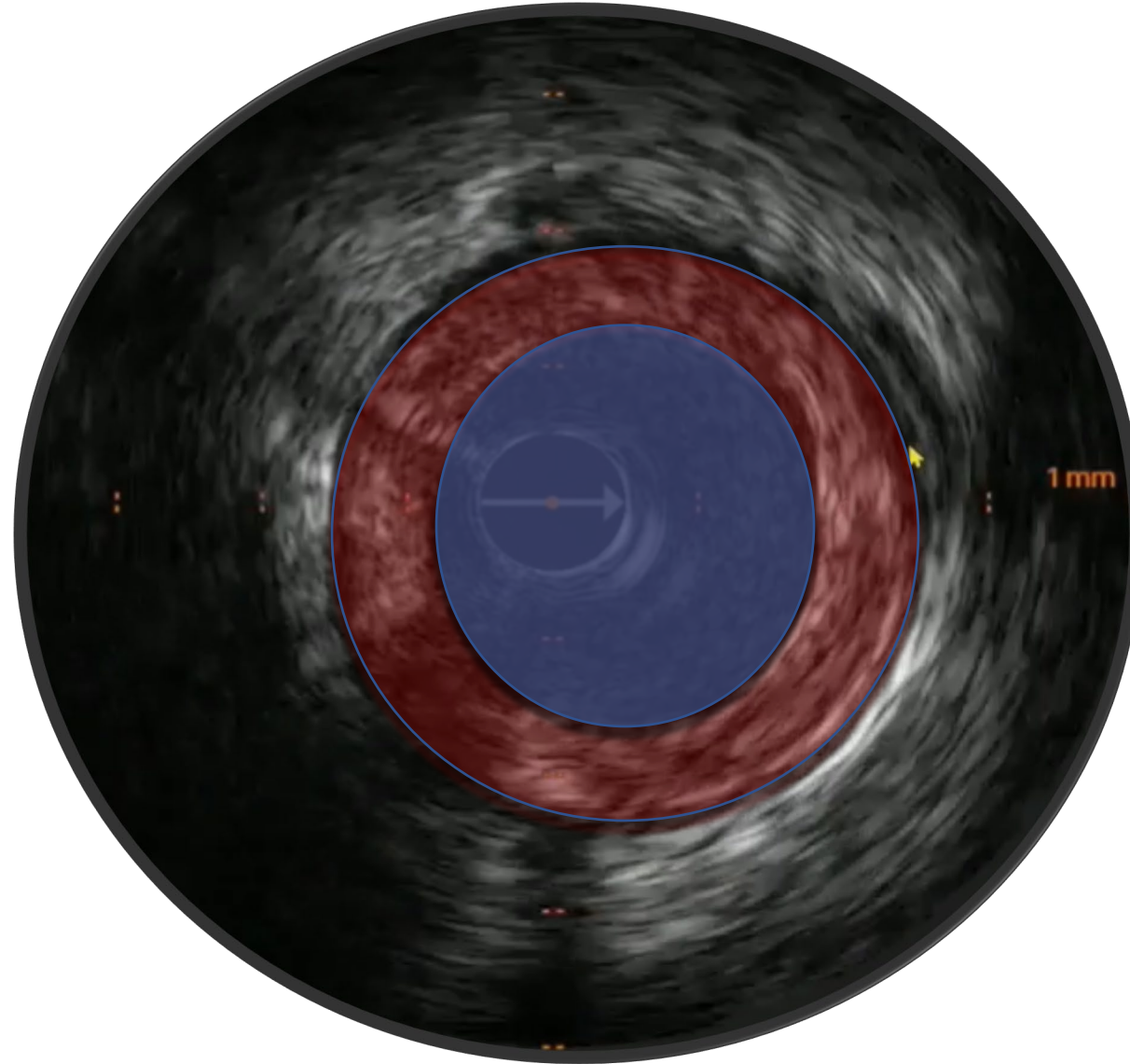
Lumen area



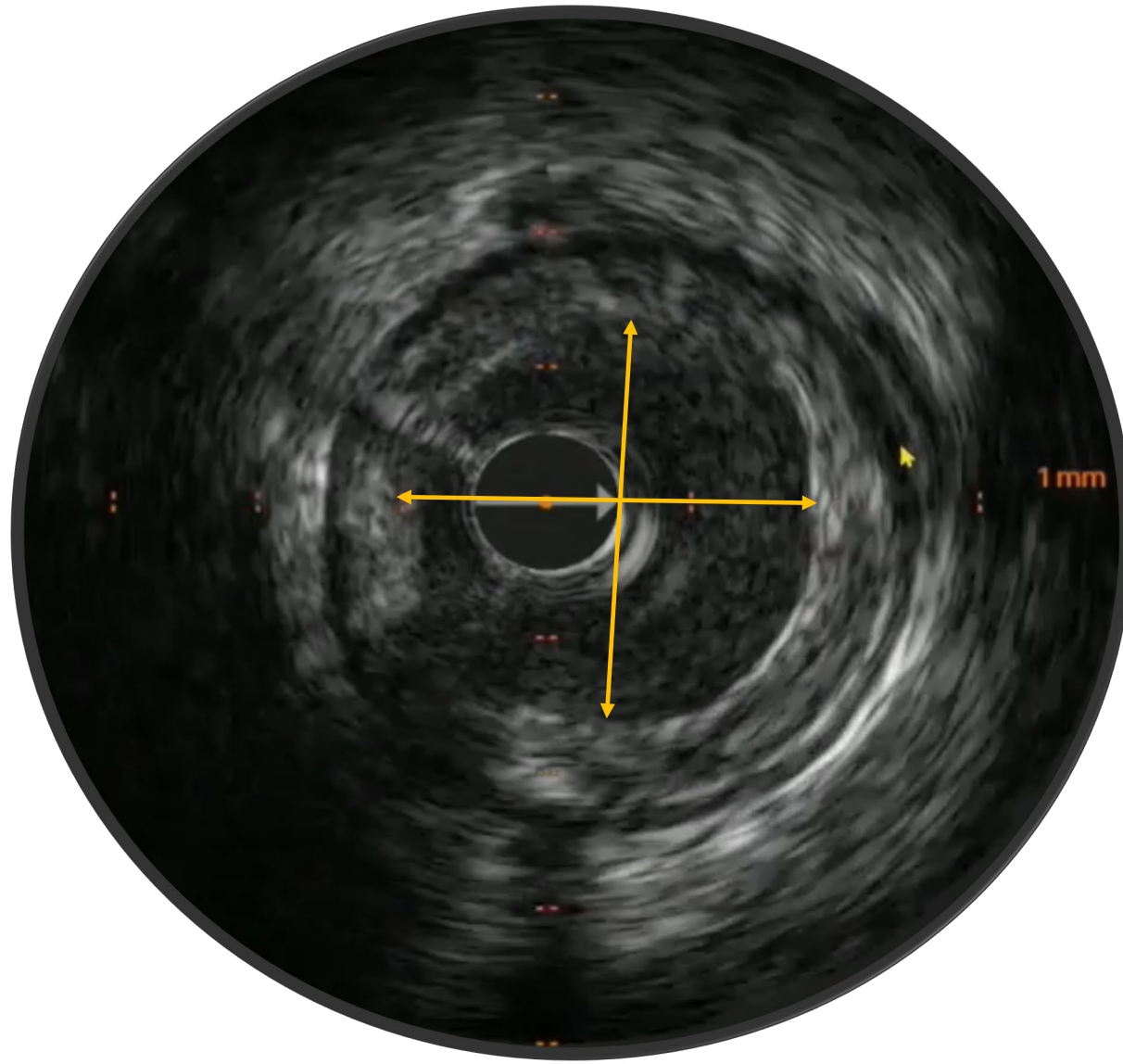
Vessel area



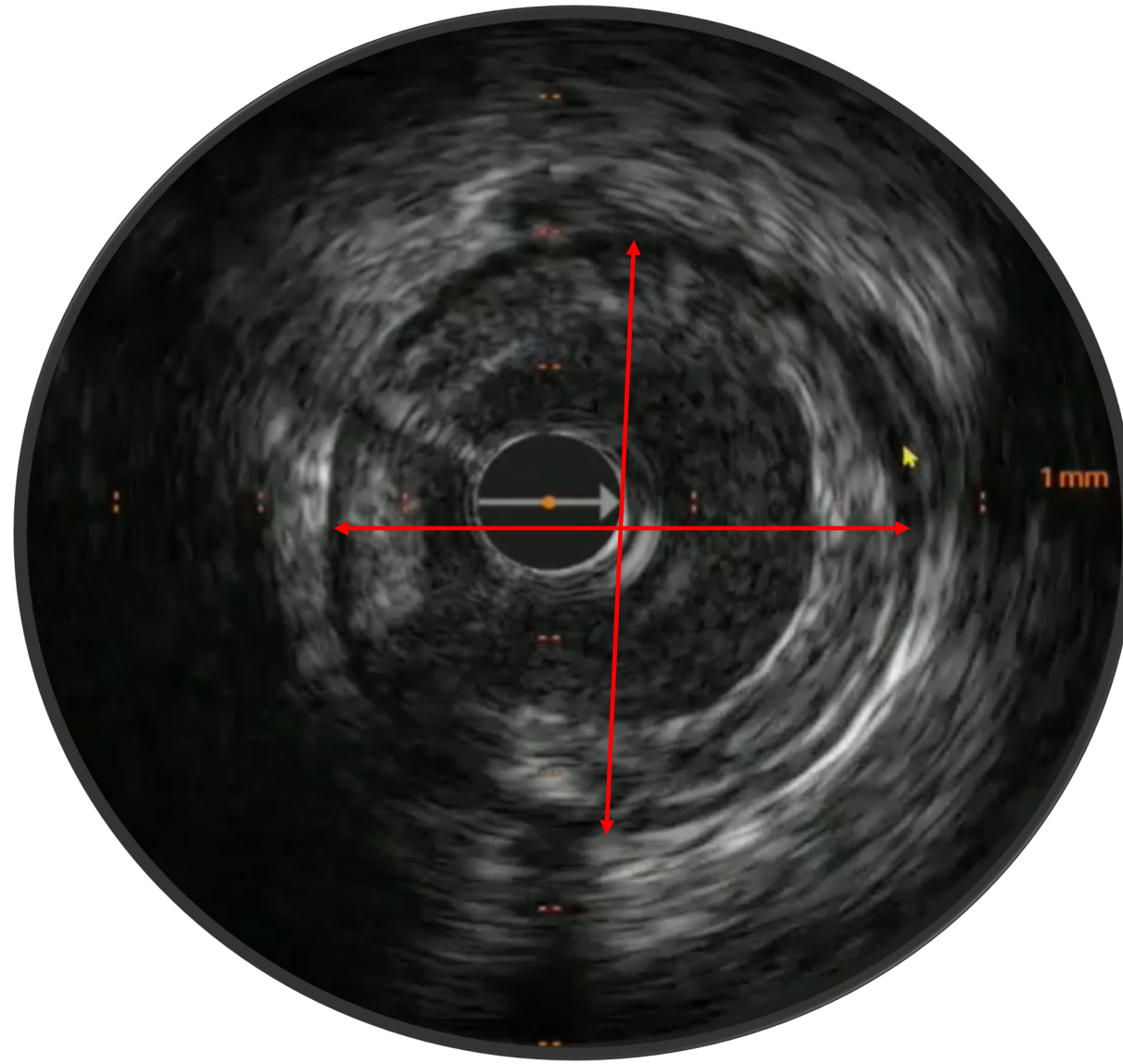
Plaque Burden



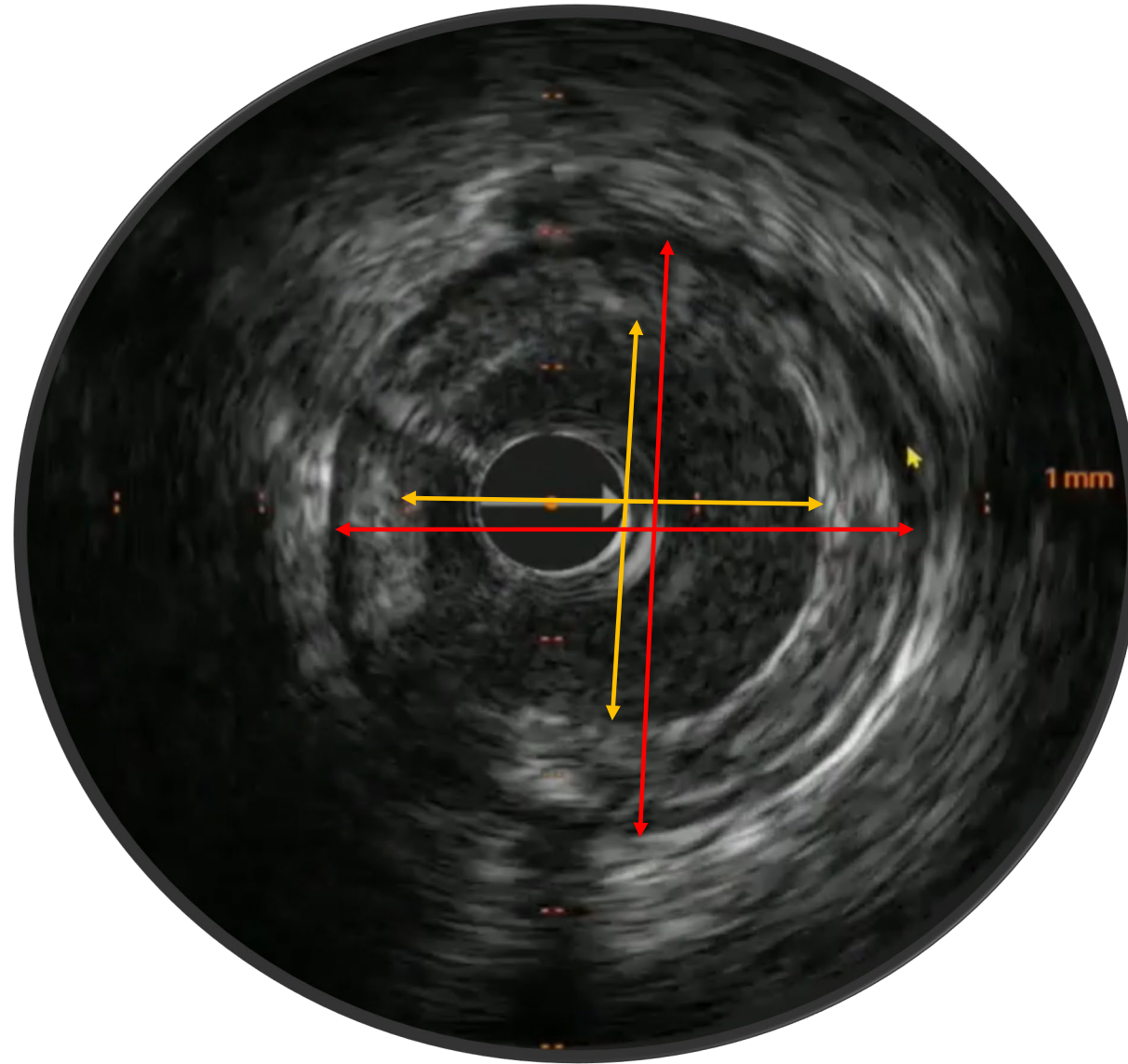
Lumen Measurements



Vessel Measurements

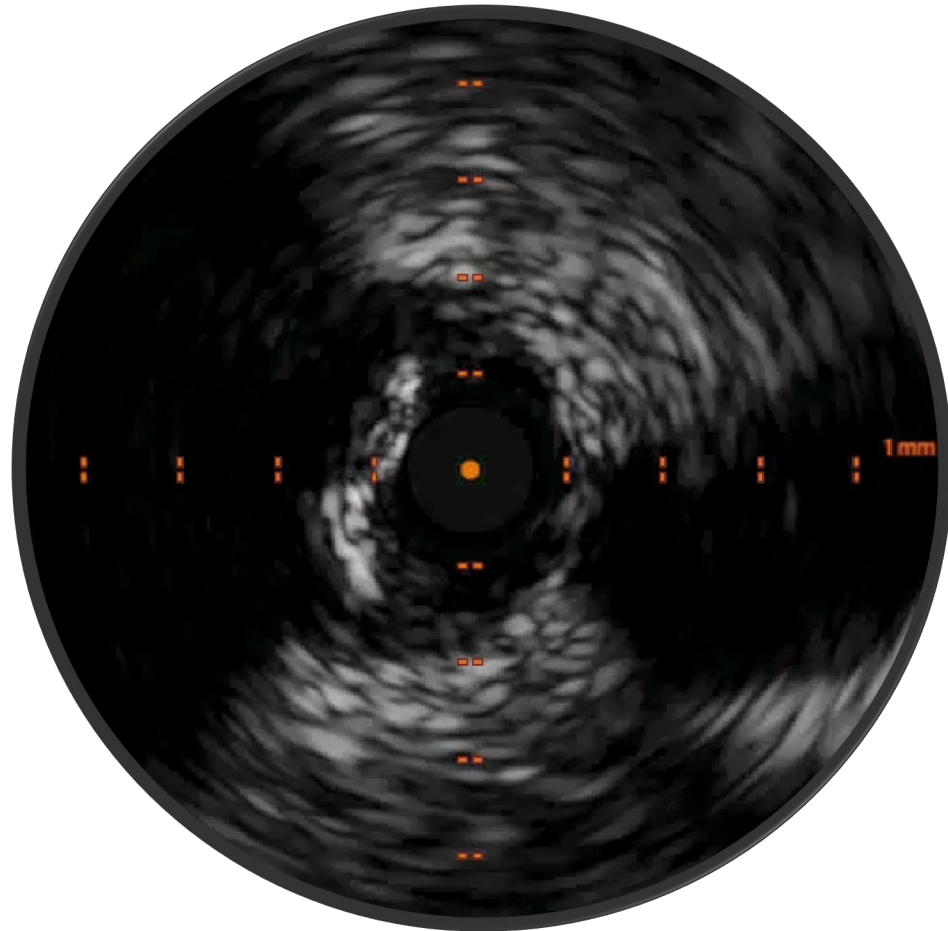


Lumen vs. Vessel Measurements



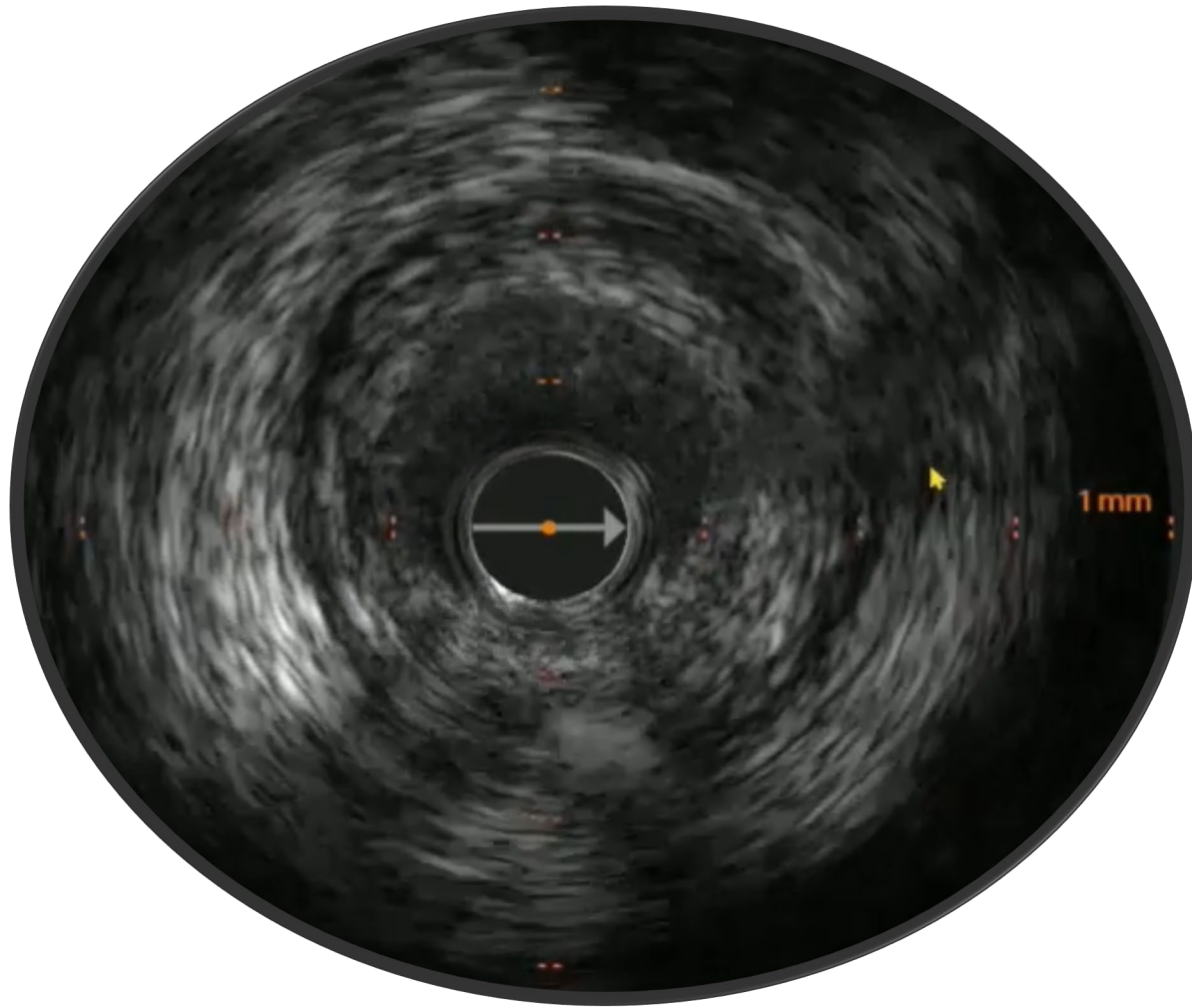
Morphology

Calcium



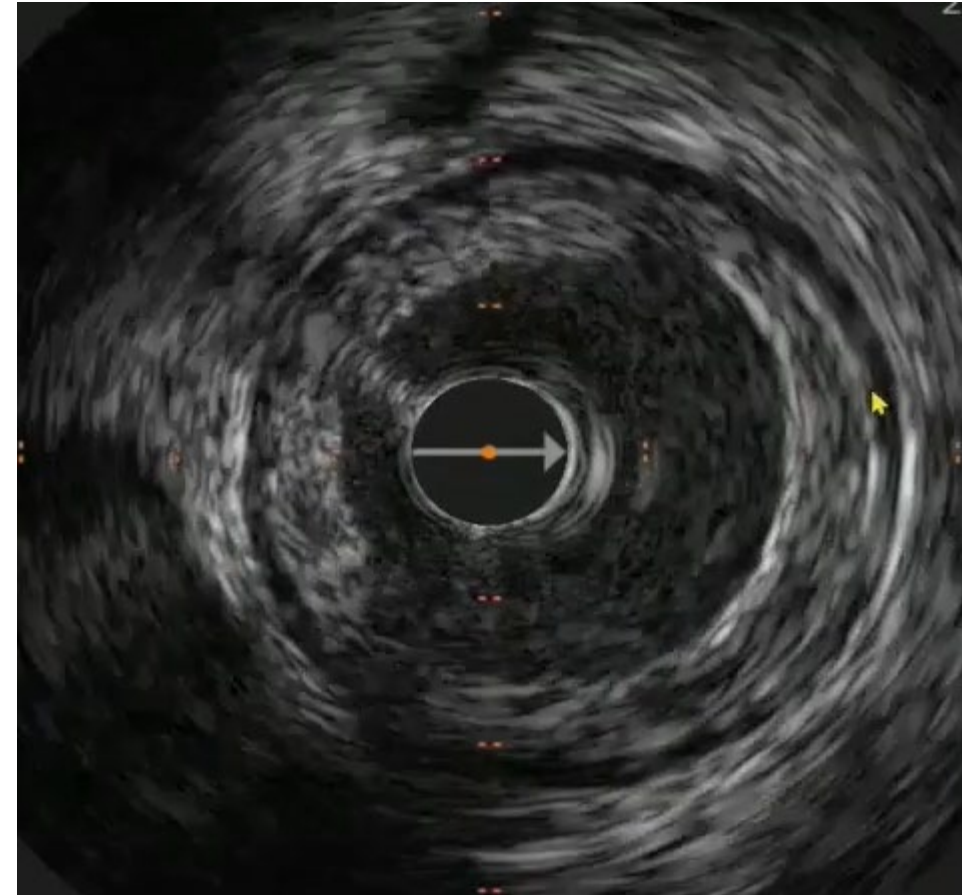
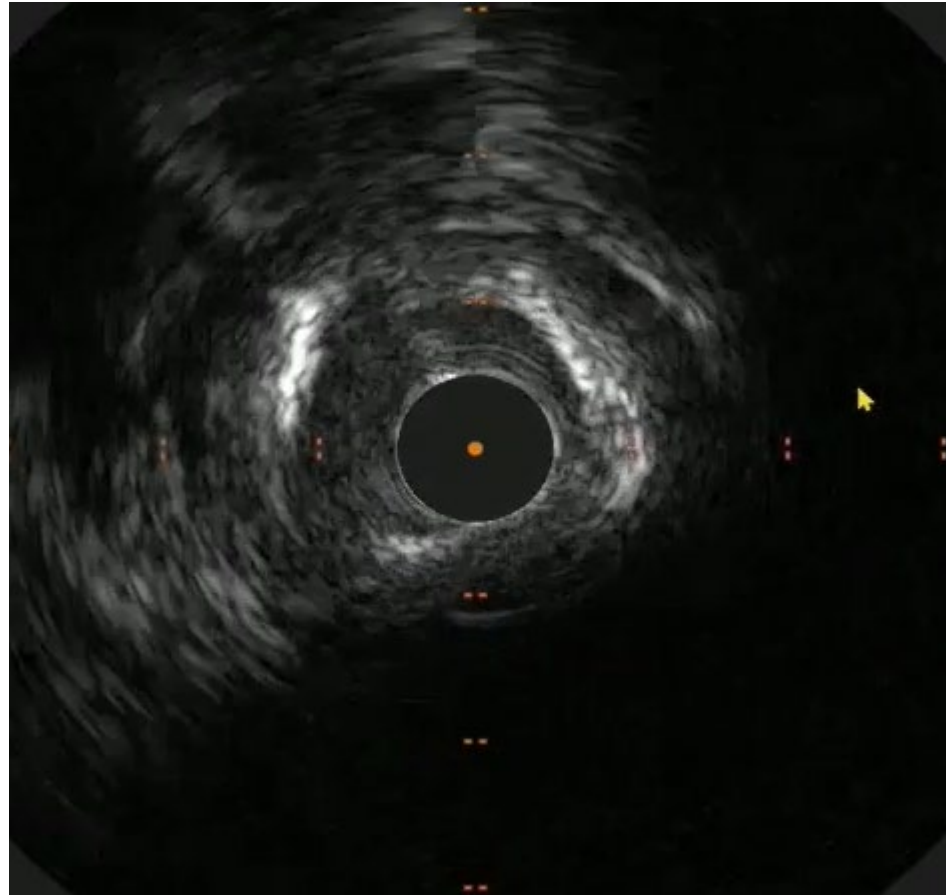
- Sound is reflected by Calcium crystal
- Reflection (echo) of sound obscures intima
- Bright white
- Characteristic shadowing arc behind bright band (dropout behind plaque)

Fibrous plaque

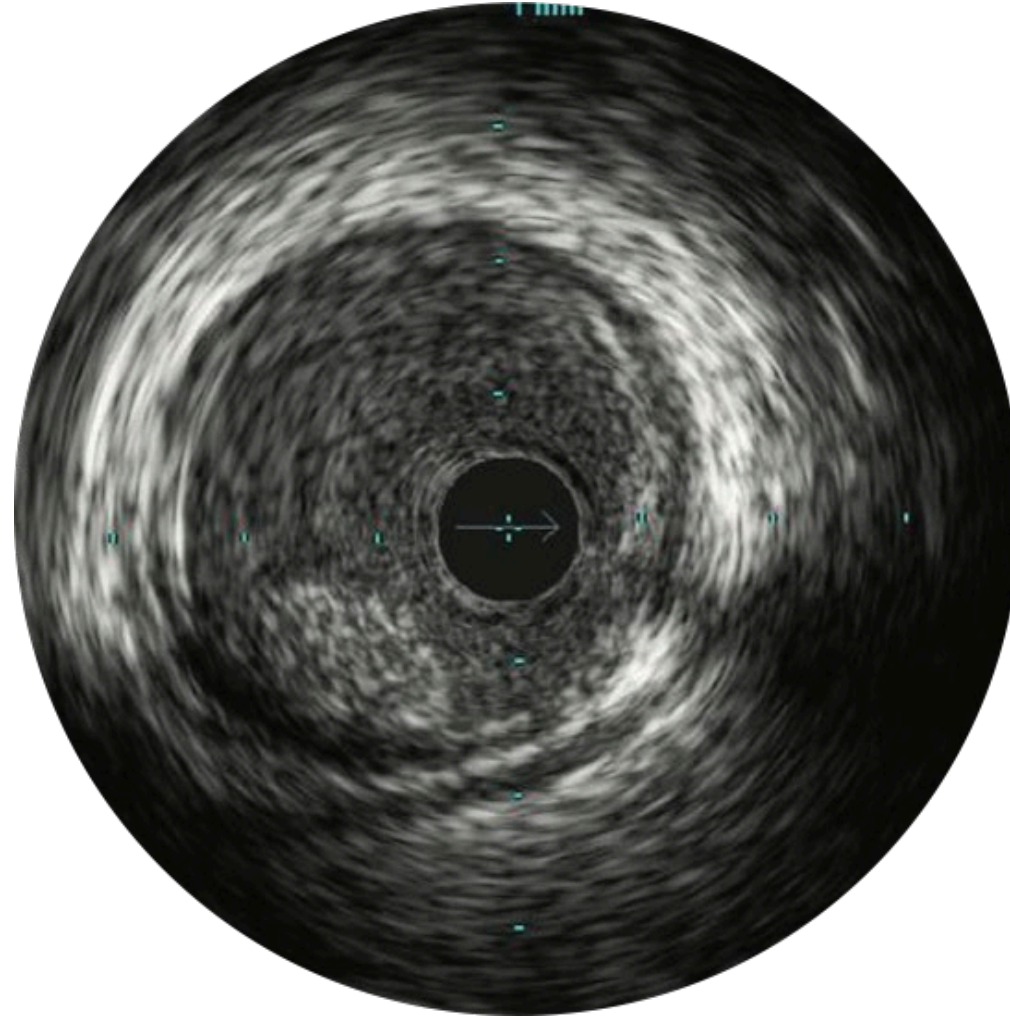


- Partial reflection of ultrasound
- No signal dropout

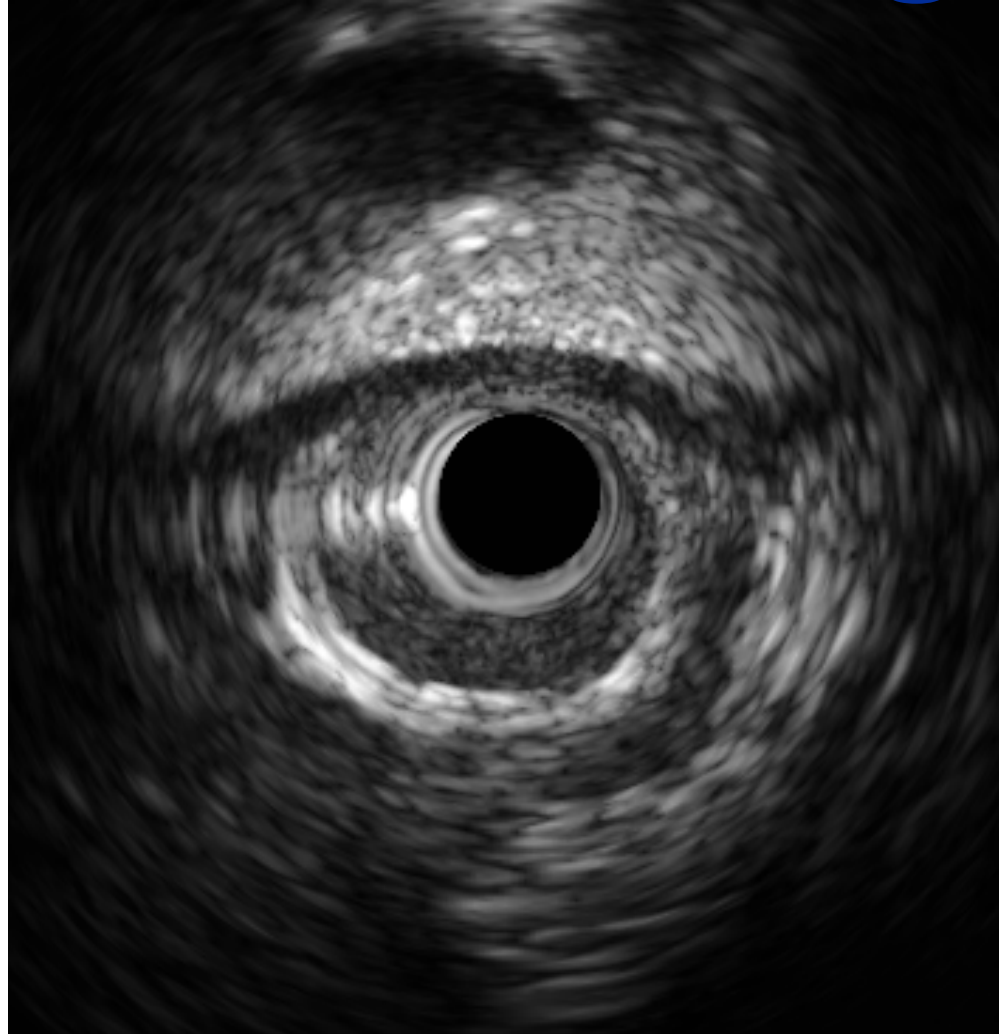
Preferred landing zone?



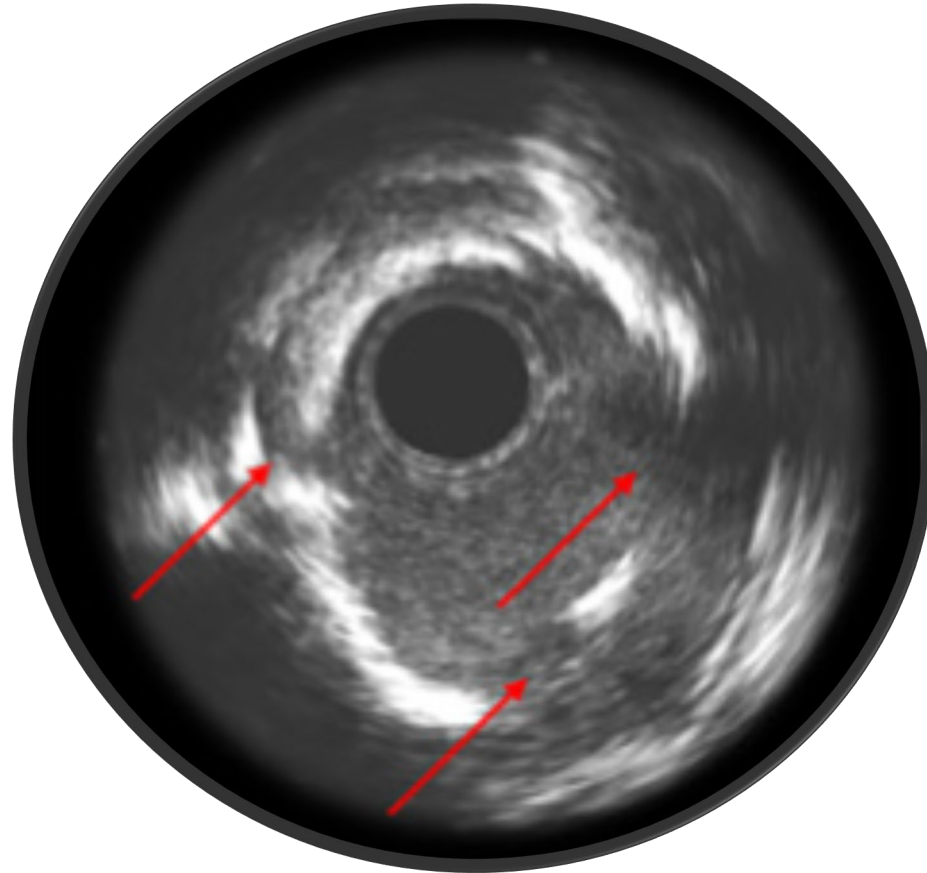
Intraluminal thrombus



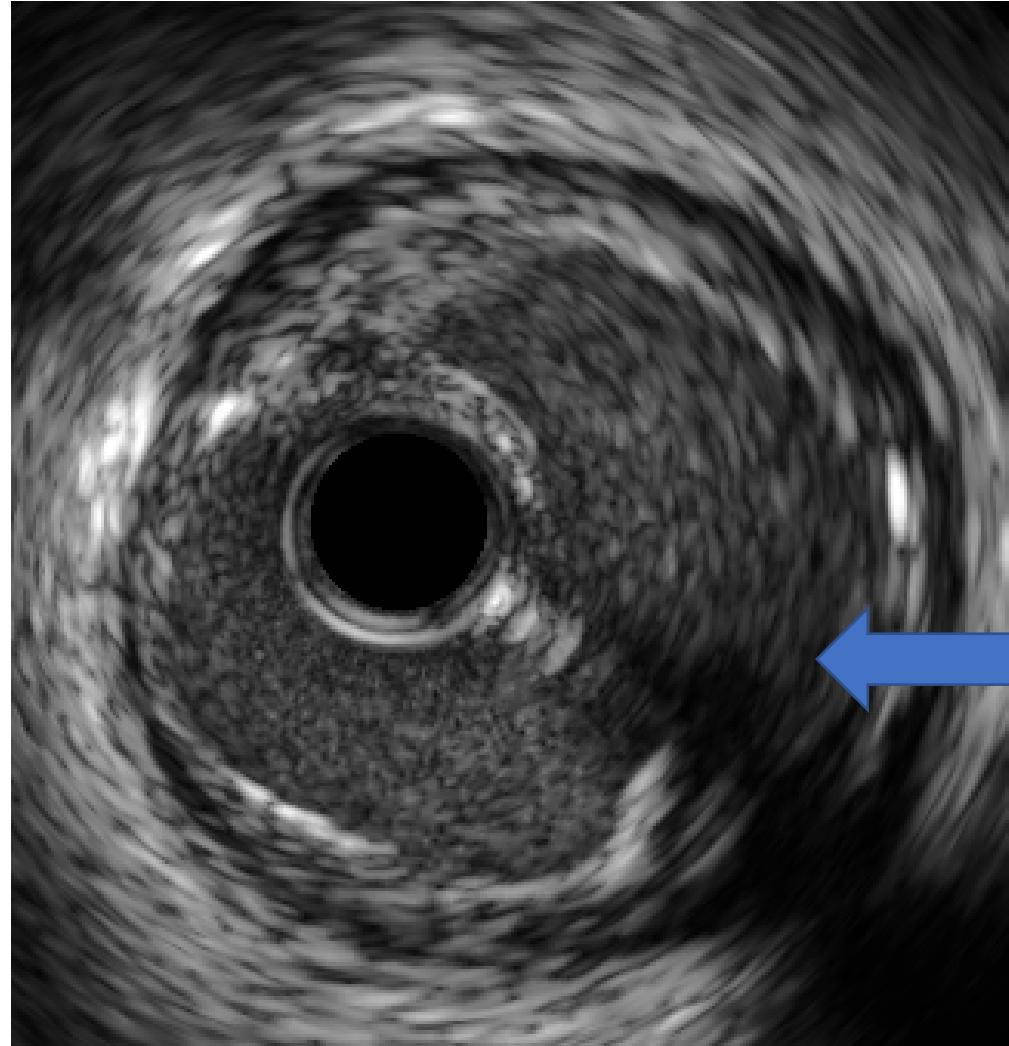
Myocardial Bridge



Calcium Fracture

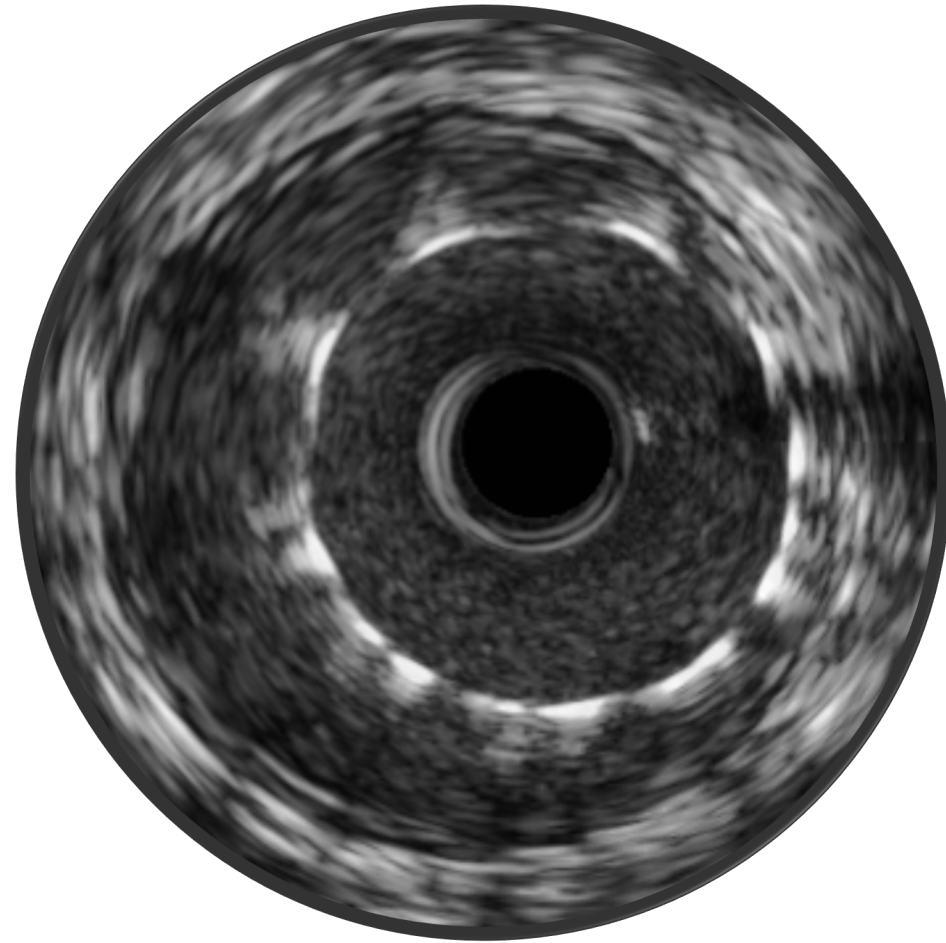


Plaque rupture

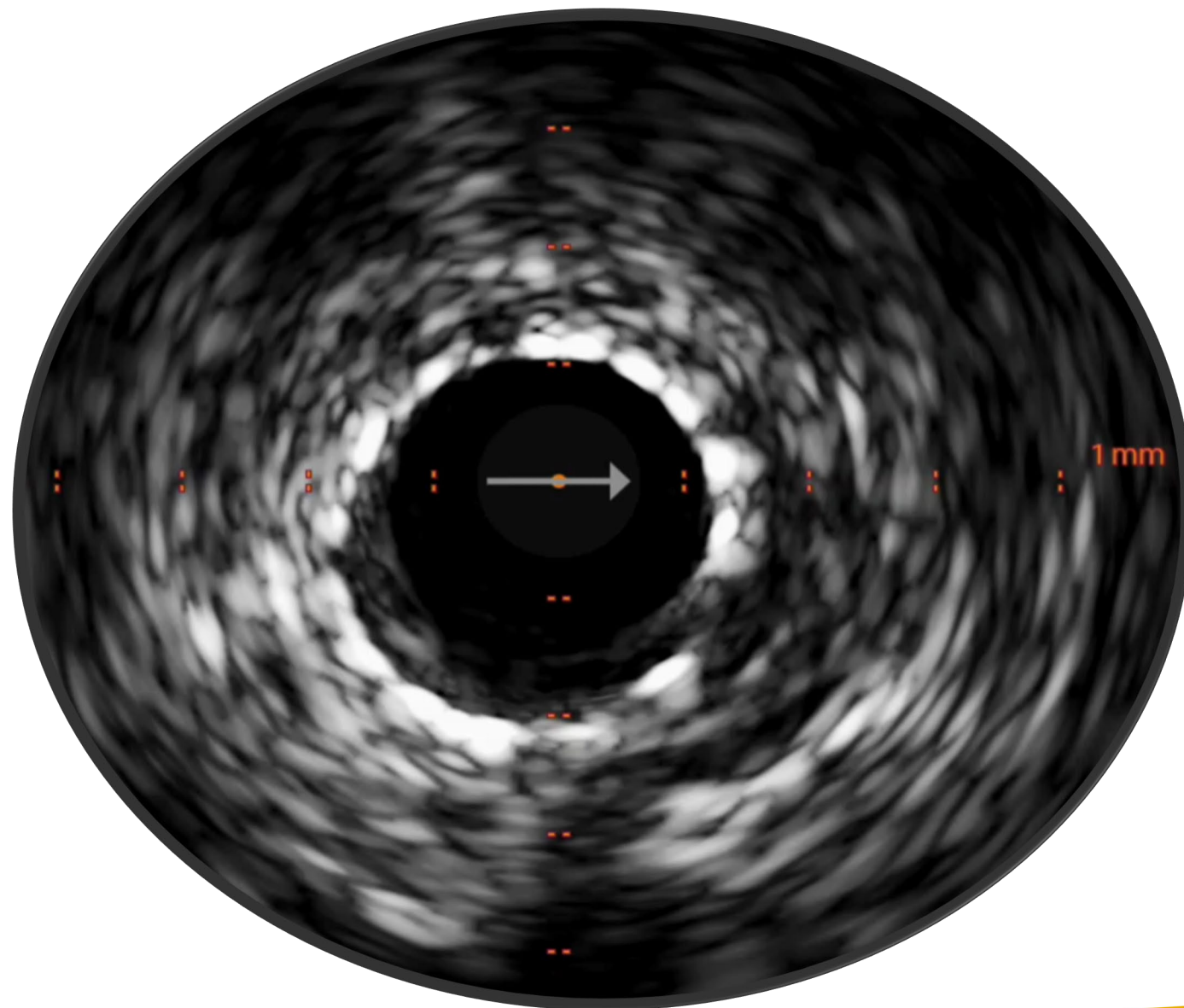


Post-PCI Assessment

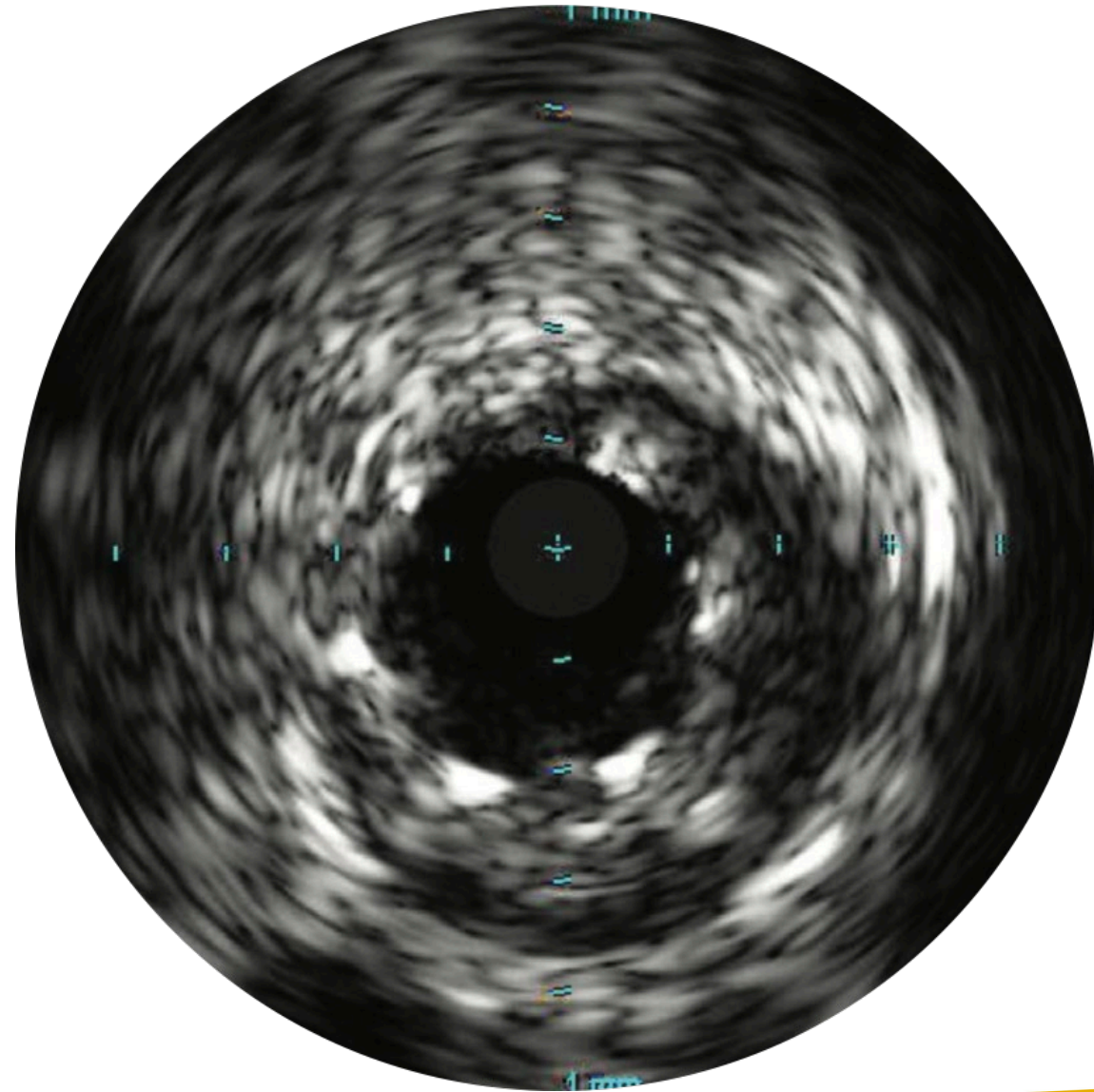
Malapposition



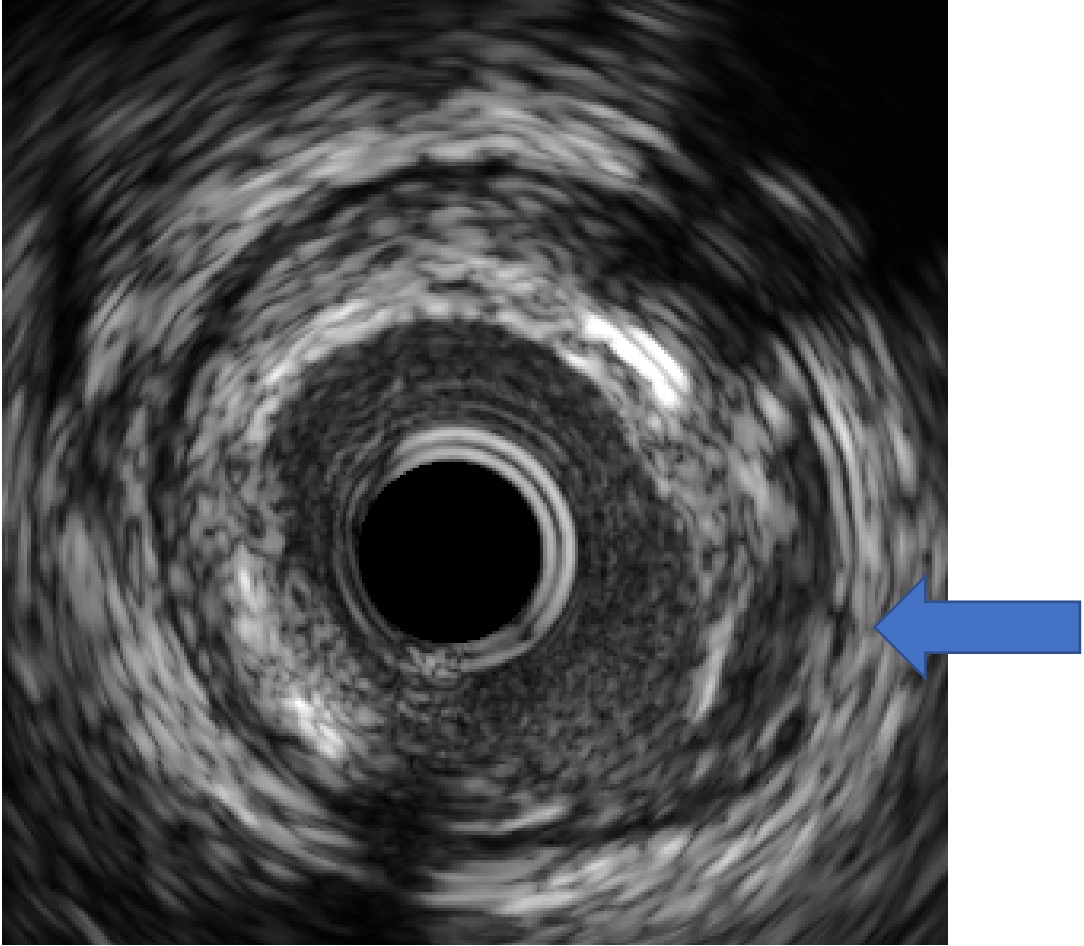
Apposition



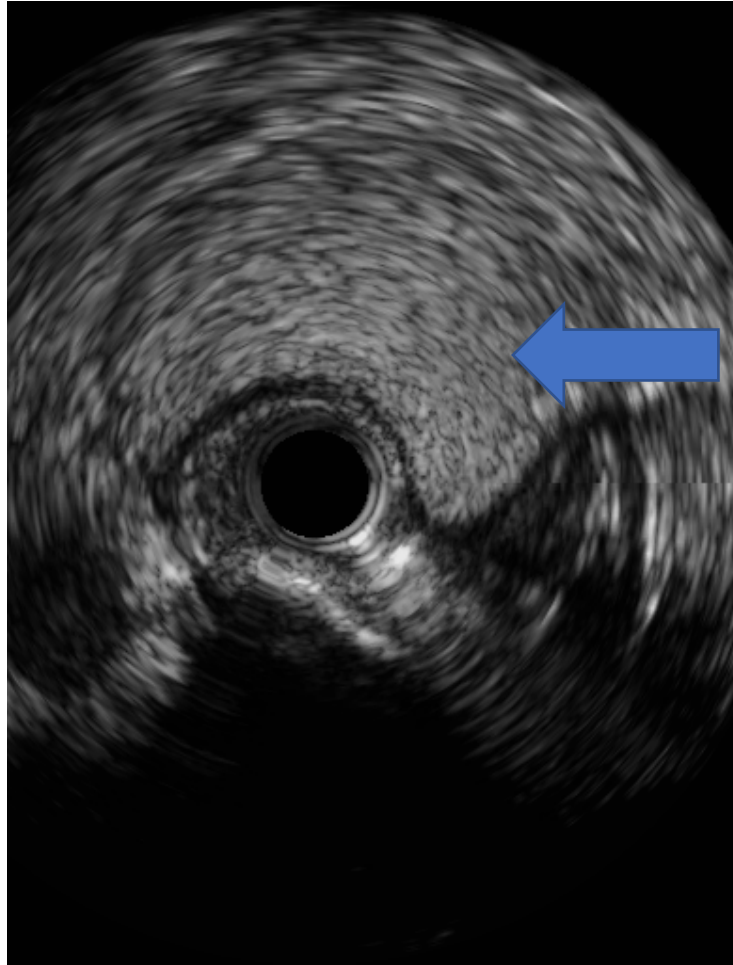
Stent Underexpansion



Dissection

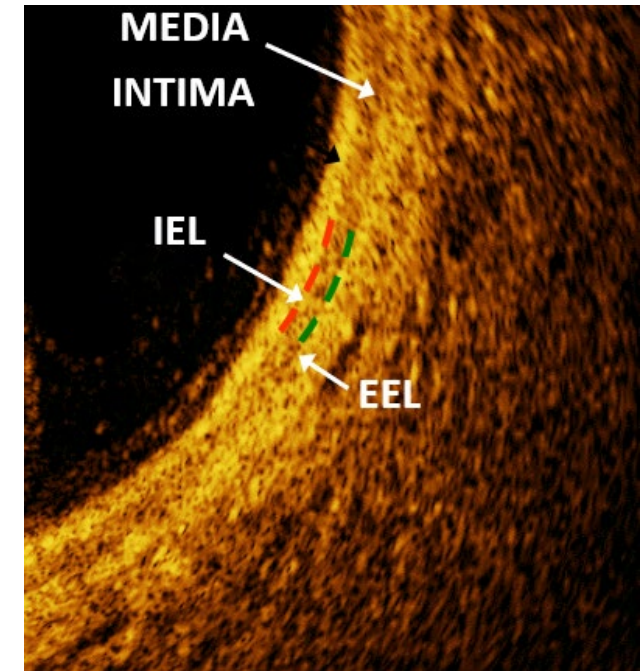
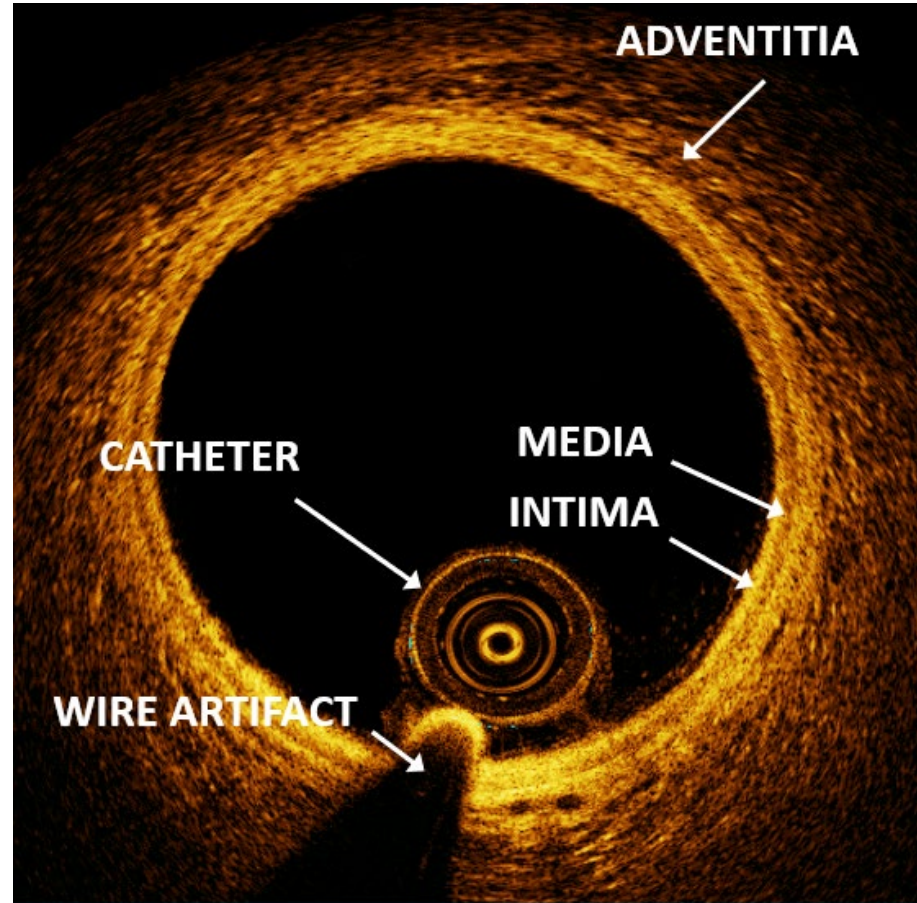


Intramural Hematoma



Normal Artery Morphology on OCT

- **Intima** = hard sponge
- **IEL** = rubber band
- **Media** = soft rope
- **EEL** = rubber band
- **Adventitia** = mesh



OCT Image Interpretation

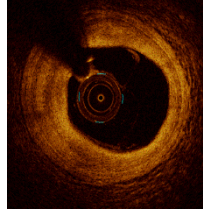
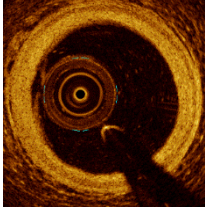
Can the EEL (rope) and Adventitia (mesh) be visualized?

YES

NO

Normal Artery

Fibrous Plaque



Is the signal change in the lumen or the wall?

Lumen

Wall

High Attenuation
(light absorbed)

Low Attenuation
(light refracted)

High Attenuation
(light absorbed)

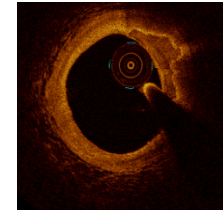
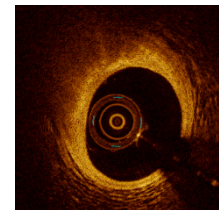
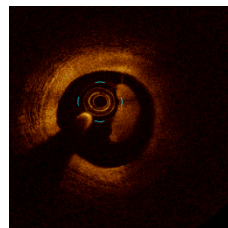
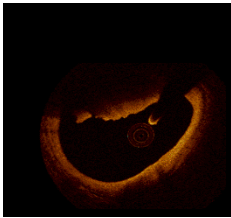
Low Attenuation
(light refracted)

Red Thrombus

White Thrombus

Lipid

Calcium



Can you draw a line around the signal change?

OCT Image Interpretation

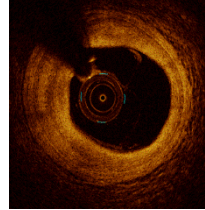
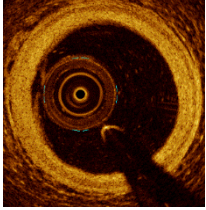
Can the EEL (rope) and Adventitia (mesh) be visualized?

YES

NO

Normal Artery

Fibrous Plaque



Is the signal change in the lumen or the wall?

Lumen

Wall

High Attenuation
(light absorbed)

Low Attenuation
(light refracted)

High Attenuation
(light absorbed)

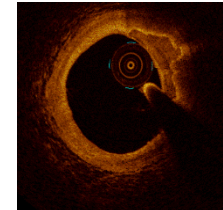
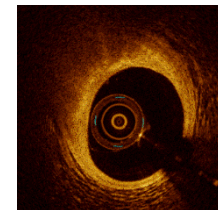
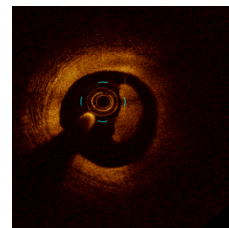
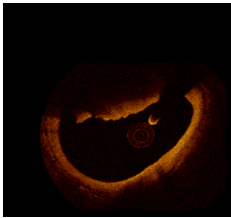
Low Attenuation
(light refracted)

Red Thrombus

White Thrombus

Lipid

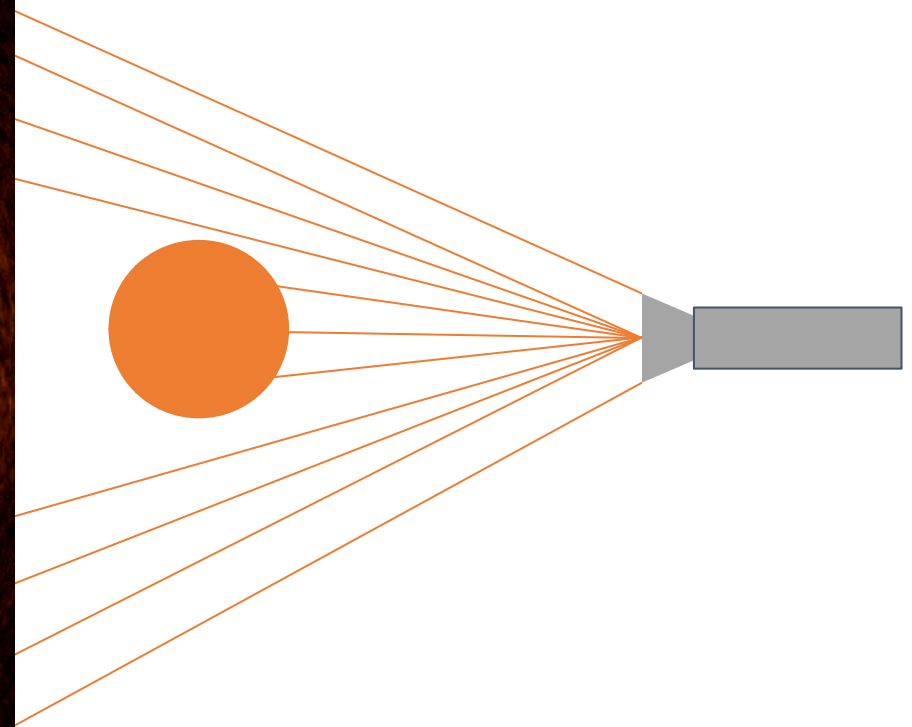
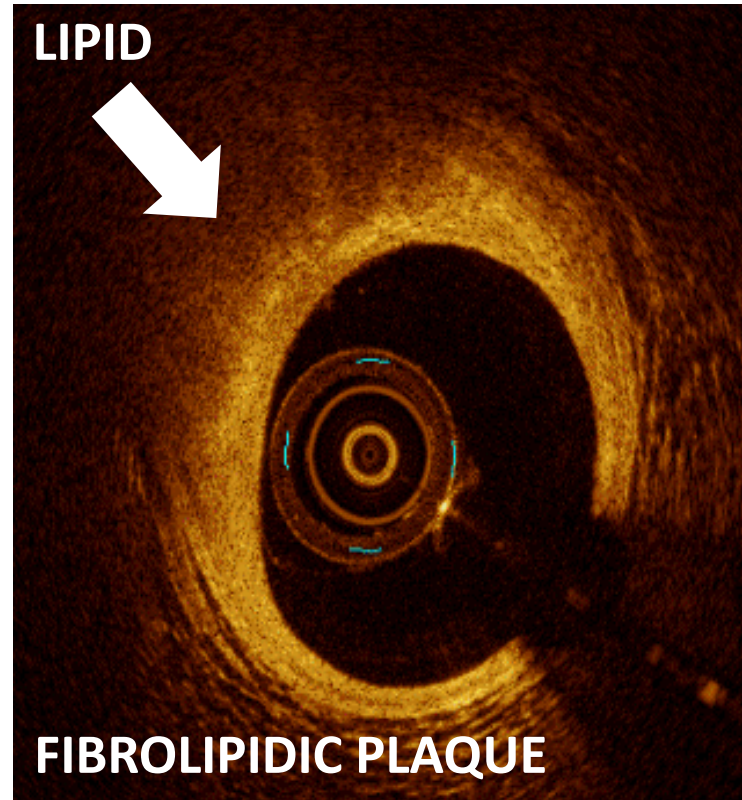
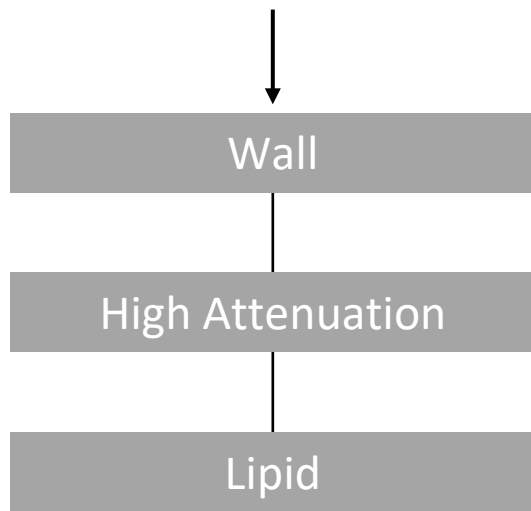
Calcium



Can you draw a line around the signal change?

OCT Image Interpretation

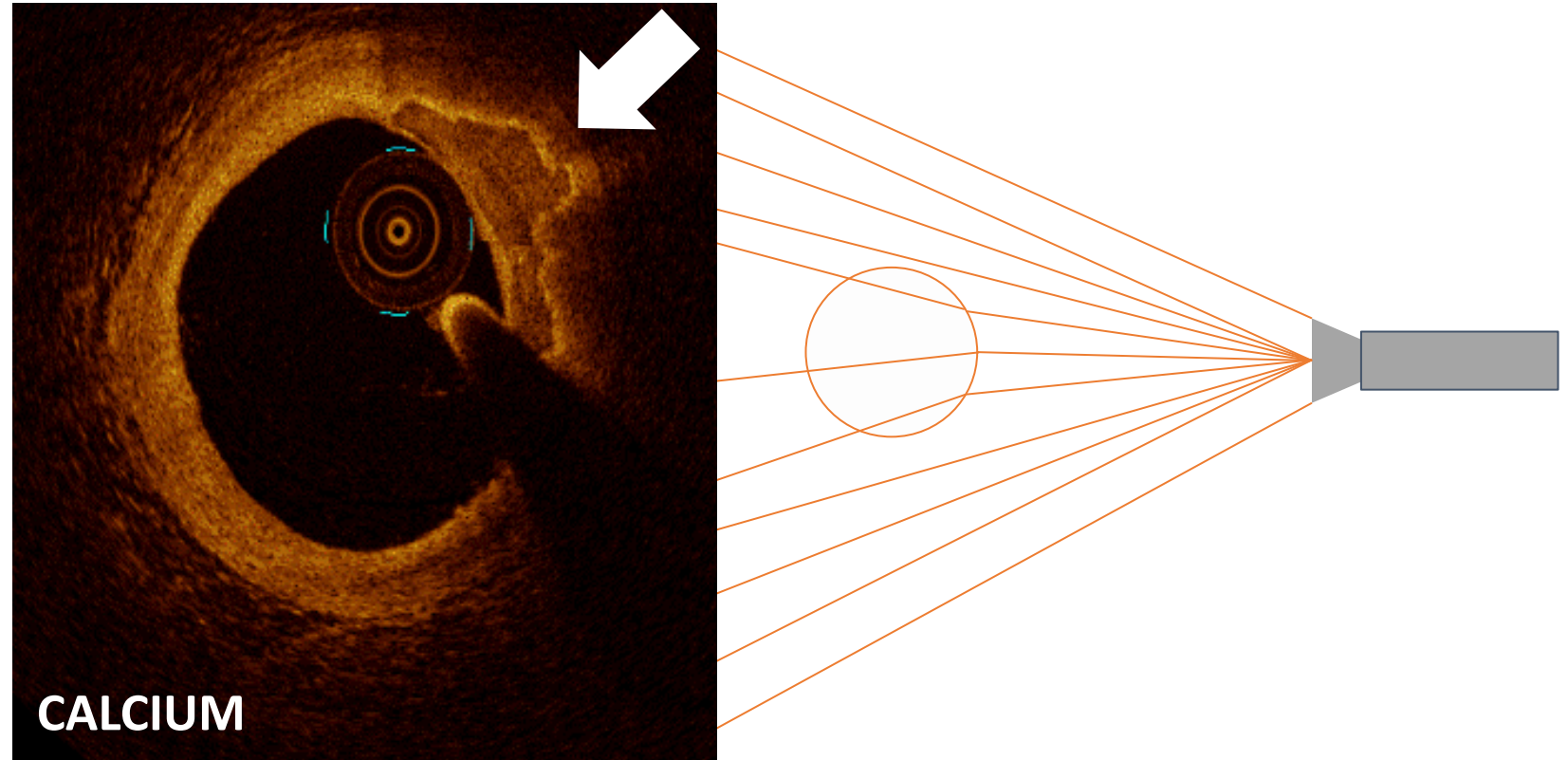
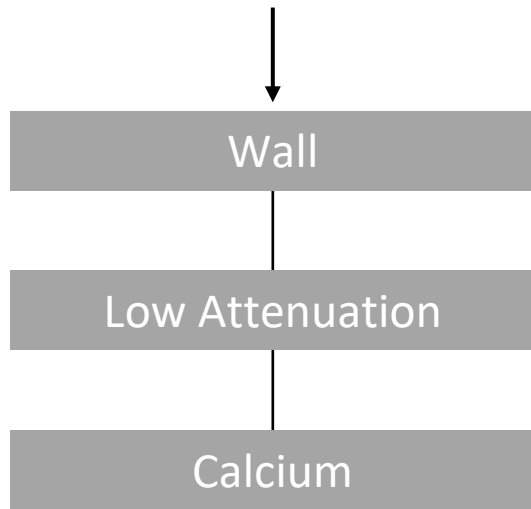
Is the signal change in the lumen or the wall?



Courtesy of Dr. Ziad A. Ali.

OCT Image Interpretation


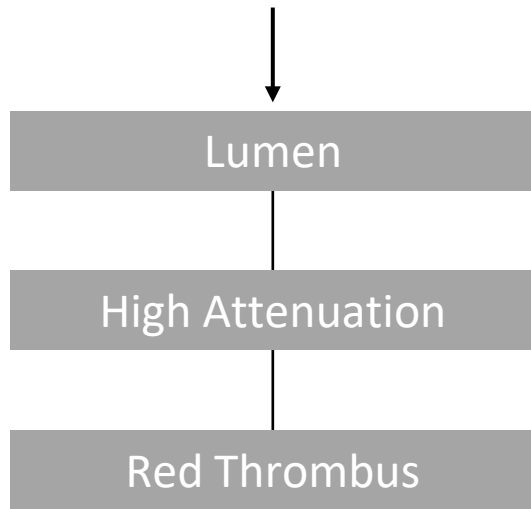
Is the signal change in the lumen or the wall?



Courtesy of Dr. Ziad A. Ali.

OCT Image Interpretation


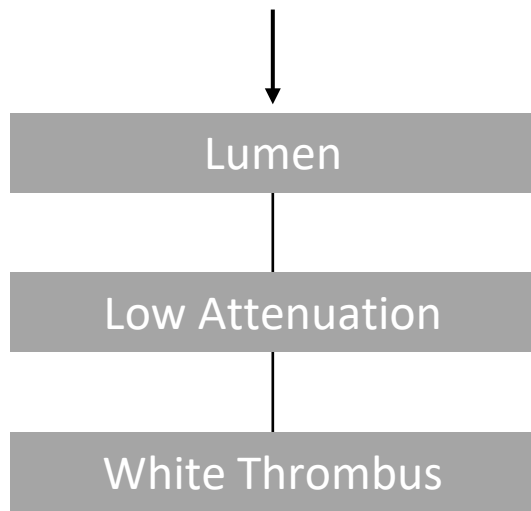
Is the signal change in the lumen or the wall?



Courtesy of Dr. Ziad A. Ali.

OCT Image Interpretation

Is the signal change in the lumen or the wall?



Courtesy of Dr. Ziad A. Ali.

OCT Image Interpretation

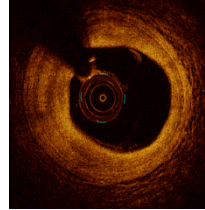
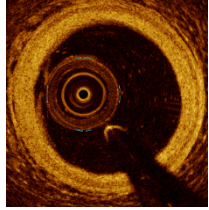
Can the EEL (rope) and Adventitia (mesh) be visualized?

YES

NO

Normal Artery

Fibrous Plaque



Is the signal change in the lumen or the wall?

Lumen

Wall

High Attenuation
(light absorbed)

Low Attenuation
(light refracted)

High Attenuation
(light absorbed)

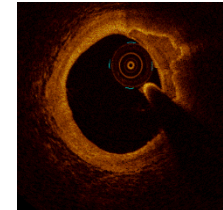
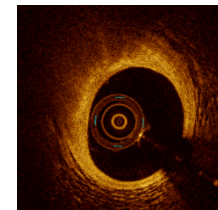
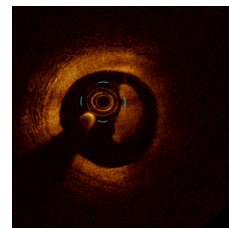
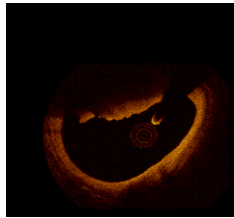
Low Attenuation
(light refracted)

Red Thrombus

White Thrombus

Lipid

Calcium



Can you draw a line around the signal change?



Not all Calcium is the same

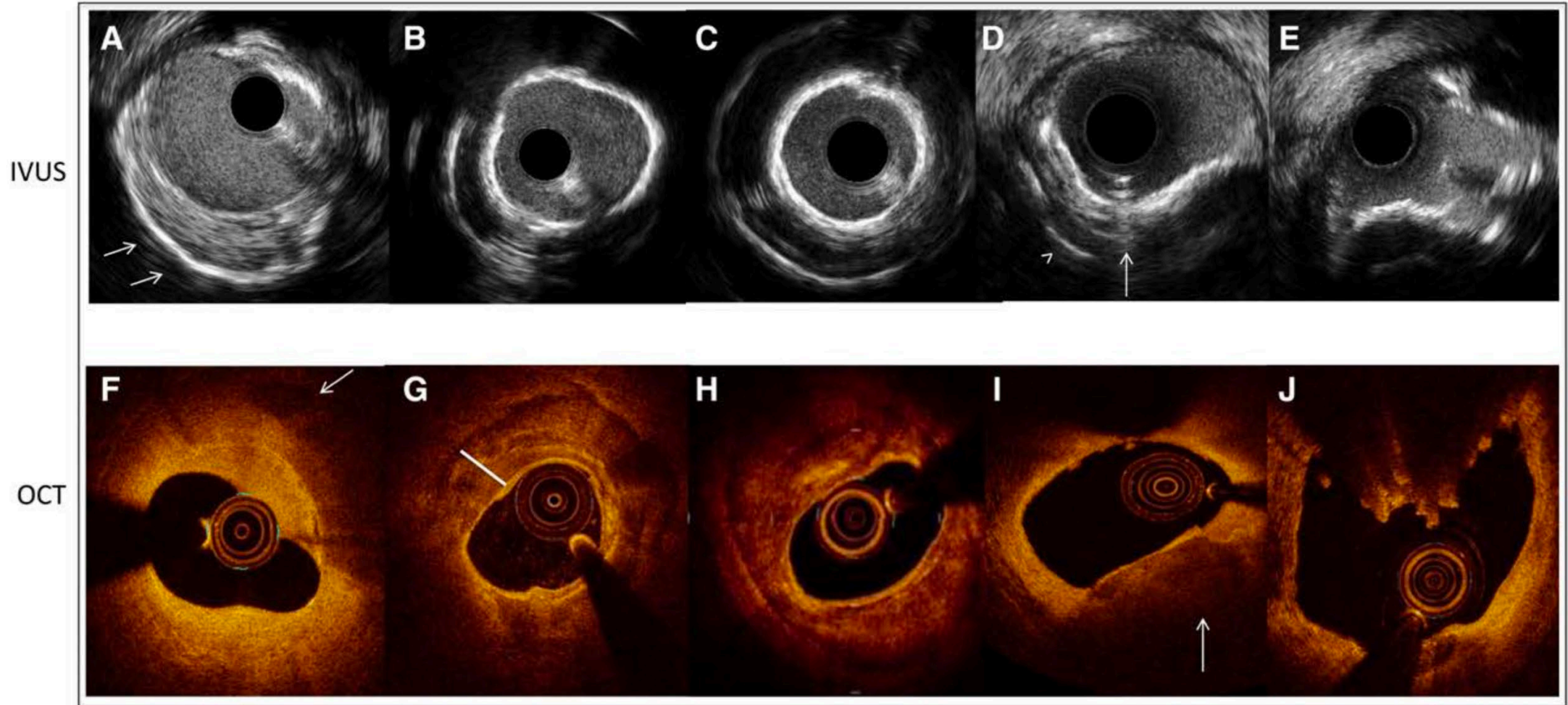
Deep calcium

Superficial calcium

Concentric calcium

Eccentric calcium

Calcified nodule



Thank you!

X:@EShlof

Web: www.OPCI.Live