CAMP PCI™

Coronary Artery & Myocardial Protected

Calcified, Torturous Anatomy: Avoiding Dissections, Perforations, and Distal Embolization

Thom G. A. Dahle, MD, FACC, FSCAI

St. Cloud Hospital, St. Cloud, MN

CentraCare™

Disclosures

Proctor/Speaker- CSI, Abiomed, Medtronic, Boston Scientific, Edwards Lifesciences

Research Grants- Edwards Lifesciences

Learning Objectives

1. Provide an overview of the importance of thorough vessel preparation in order to optimize outcomes during a PCI procedure.
2. Discuss complications associated with coronary calcium and severe tortuosity.
3. Discuss best practices for adequate vessel preparation and avoidance of dissection, perforation, embolization.

Coronary Anatomic Features That Increase Procedural Complexity

- **Presence of Calcium (High Calcium burden)**
- **Severe tortuosity**
- Bifurcation with severe side branch lesion
- Chronic total occlusion
- Unprotected left main
- SVG
- Last remaining conduit
- Thrombus content
- Diffuse atherosclerotic burden

Complications associated with coronary calcium

- Prone to dissection during balloon angioplasty[1] or pre-dilatation
- Difficult to completely dilate[2]
- May prevent adequate stent expansion[3]
- Prevent stent delivery to the desired location[4]
- Uneven drug distribution associated with restenosis[5]

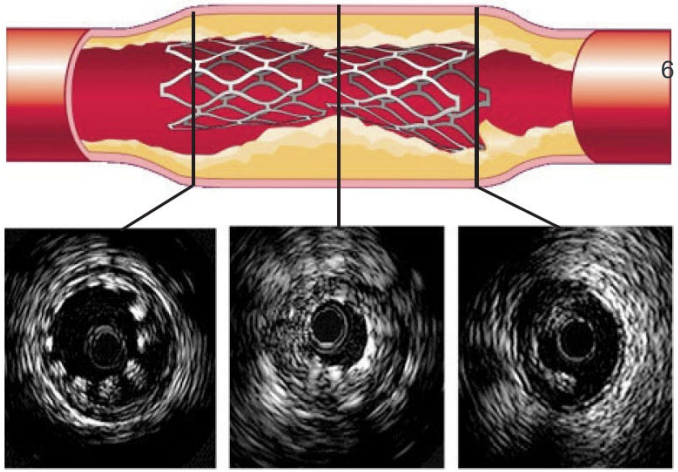

Figure 6. Shows incomplete apposition, incomplete expansion and an edge tear.

1 Fitzgerald PJ, et al.. Circulation. 1992:86;64-70. Kahn J, et al. Cathet Cardiovasc Diagn. 1990;21:89-91.
2 Cavusoglu E, et al. Cathet Cardivasc Intervent. 2004;62:485-498.
3 Moussa I, et al. Circulation. 1997;96(1):128-136.
4 Gilutz H, et al. Cathet Cardiovasc Intervent. 2000;50:212-214.
5 Nakano M, et al. Eur Heart J. 2013;34:3304-3313.
6 Buckley CJ. Vascular Disease Management. 2011;8:87-92. . Reprinted with permission from HMP Communications.

Patients with severe calcifications are less likely to have complete revascularization

	All studied patients (n=6296)	Patients with severely calcified lesions (n=1291)	Patients without severe calcifications (n=5005)	p Value
Age (years)	64 (56–72)	69 (62–75)	63 (55–71)	<0.001
Male (%)	4740 (75.3)	957 (74.1)	3783 (75.6)	0.280
BMI	27.1 (24.7–30.0)	27.0 (24.2–30.0)	27.2 (24.8–30.1)	0.001
Hypertension	4328 (69.4)	969 (75.5)	3359 (67.7)	<0.001
Hypercholesterolaemia (%)	4056 (65.2)	899 (70.2)	3157 (63.9)	<0.001
Diabetes mellitus (%)	1453 (23.2)	1079 (21.7)	374 (29.0)	<0.001
Peripheral vascular disease (%)	1745 (30.7)	397 (32.1)	1348 (30.3)	0.214
Cerebrovascular disease (%)	182 (4.9)	73 (7.2)	109 (4.0)	<0.001
Creatinine > 200 mol/L	61 (1.1)	20 (1.6)	41 (0.9)	0.025
Positive smoking history (%)	3257 (52.1)	648 (50.4)	2609 (52.6)	0.161
LV systolic function				**0.712**
Normal LV function (%)	3838 (78.4)	833 (77.6)	3005 (78.7)	
Moderate LV dysfunction (%)	865 (17.7)	196 (18.2)	669 (17.5)	
Severe LV dysfunction (%)	191 (3.9)	45 (4.2)	146 (3.8%)	
Unstable presentation (%)	3349 (53.2)	672 (52.1)	2677 (53.5)	0.357
History of previous MI (%)	1745 (30.7)	397 (32.1)	1348 (30.3)	0.214
Syntax score	15 (9–23)	25 (18–34)	13 (7–20)	<0.001
Complete revascularisation (%)	1086 (53)	339 (48)	550 (55.6)	0.001
Treatment with 2nd generation DES (%)	2709 (43.0)	375 (29.0)	2334 (46.5)	<0.001

BMI, Body Mass Index; MI, myocardial infarction; DES, drug-eluting stent.

Christos V Bourantas et al. Heart 2014;100:1158-1164

Severe Coronary Calcium is Underestimated

- Standard angiography underestimates coronary calcification.[1]
- Mintz et. al. concluded “IVUS analysis shows that target lesion calcification is ubiquitous in coronary artery disease.”[1]
- Calcification was seen in 38% of coronary lesions via angiogram and in 73% via IVUS.[1]
- Despite being a relatively common problem there have been few FDA IDE PMA trials studying only patients with severe coronary calcification.
- Due to poor clinical outcomes, including higher MACE and angiographic complications, patients with severe calcium have been excluded from many large scale clinical trials.

1. Mintz , et al. Circulation. 1995 Apr 1;91(7):1959-65.

Severely Calcified Lesions are Undertreated

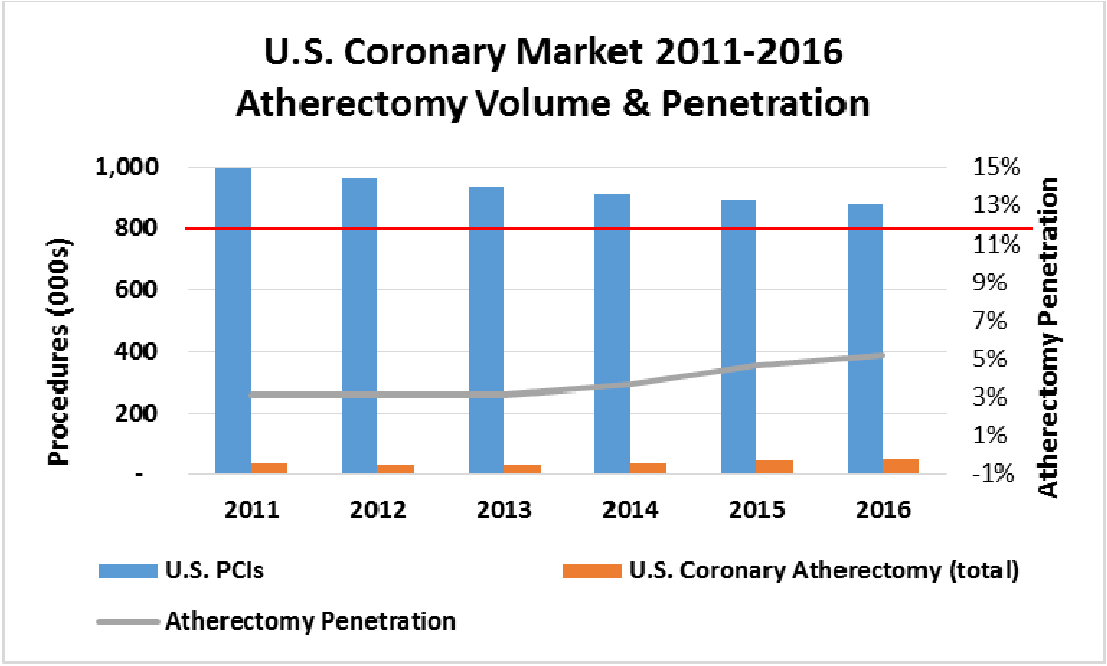

12% Severely Calcified Lesions

<5% Total Atherectomy * Penetration

* Total Atherectomy includes: Diamondback Orbital Atherectomy, Rotablator and Laser Atherectomy systems

12% severe calcium
Bourantas C, et al. Heart. 2014;0:1–7. 20% severe Ca++ in DES trials
Généreux P, et al. J Am Coll Cardiol. 2014;63(18):1845-54. 6% severe Ca++ in ACS
Feldman D, et al. Circulation. 2013;127:2295-2306. 60% of PCIs ACS, 40% stable → 12% severe Ca++

Coronary Calcium is Under-Appreciated and Worsens Long-Term PCI Outcomes

ACUITY/ HORIZONS AMI TRIALS[1]
6,855 ACS patients
1-year outcomes

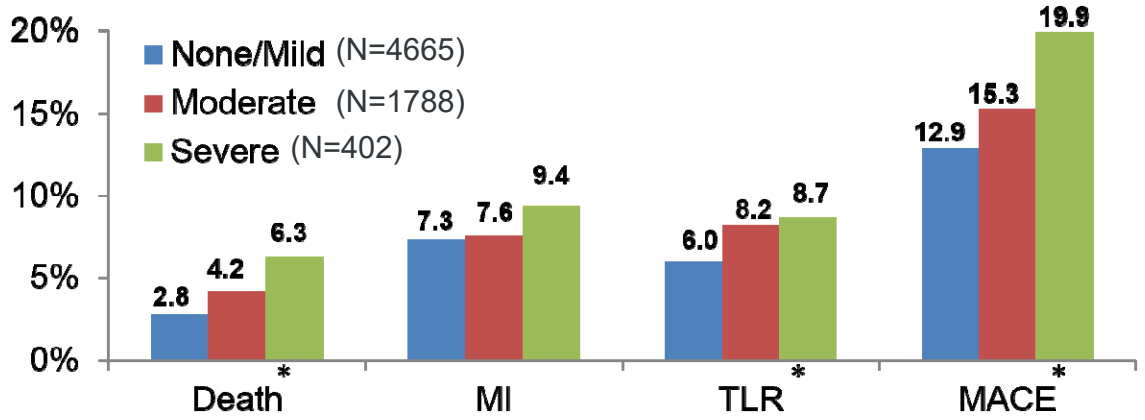

ADAPT-DES[2]
8,582 PCI patients
2-year outcomes

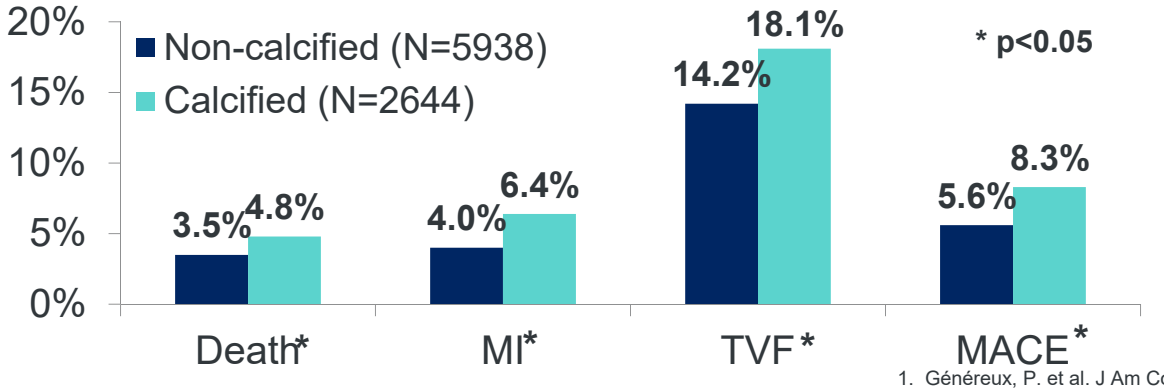

1. Généreux, P. et al. J Am Coll Cardiol 2014;63(18):1845-54
2. Généreux, P et al. Int J Cardiol. 2017 Mar 15;231:61-67

Coronary Calcium is a Predictor of Worse Prognosis after PCI with DES

7 DES Trials – 6,296 patients
Independent core lab (Cardialysis, Rotterdam)
20% of patients had severe coronary calcification
Outcomes at 3 years

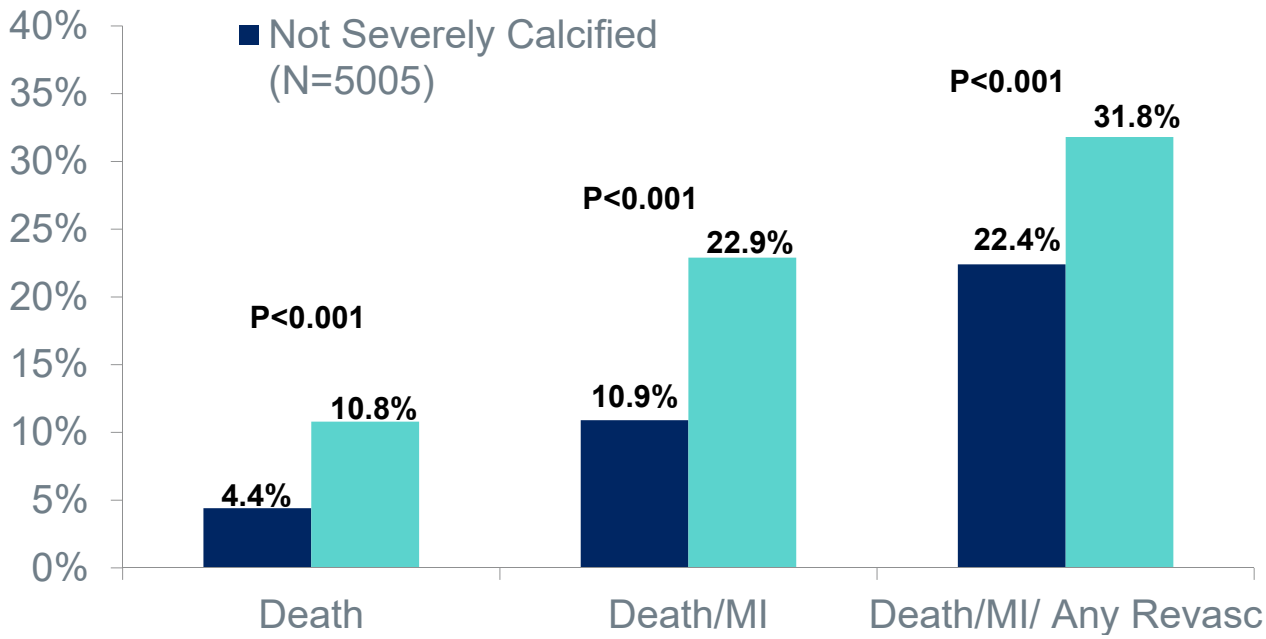

Bourantas CV, et al. Heart. 2014 Aug;100(15):1158-64.

Patients with severe calcium have higher incidence of death—myocardial infarction and death—myocardial infarction-any revascularisation

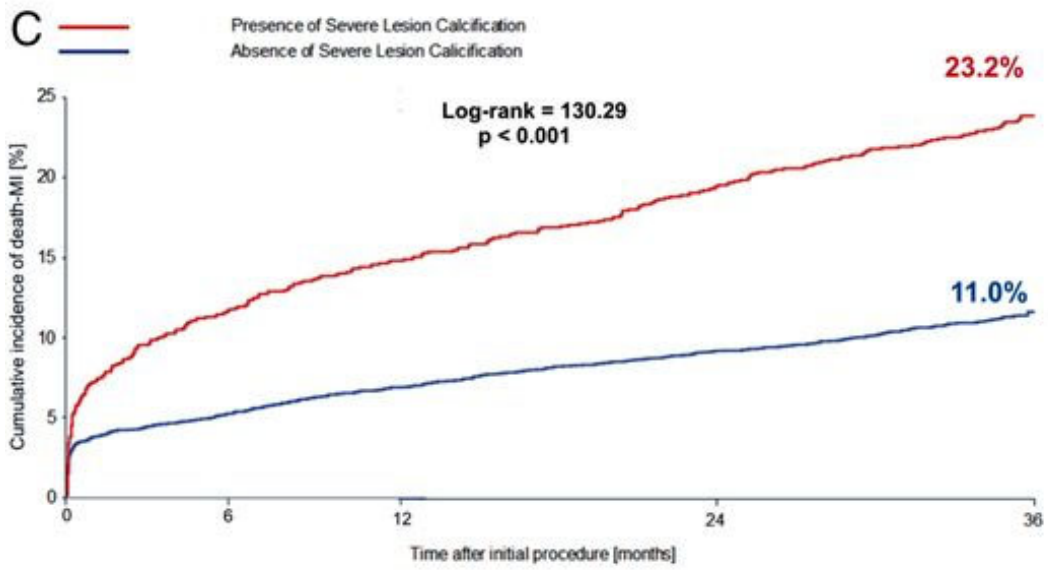

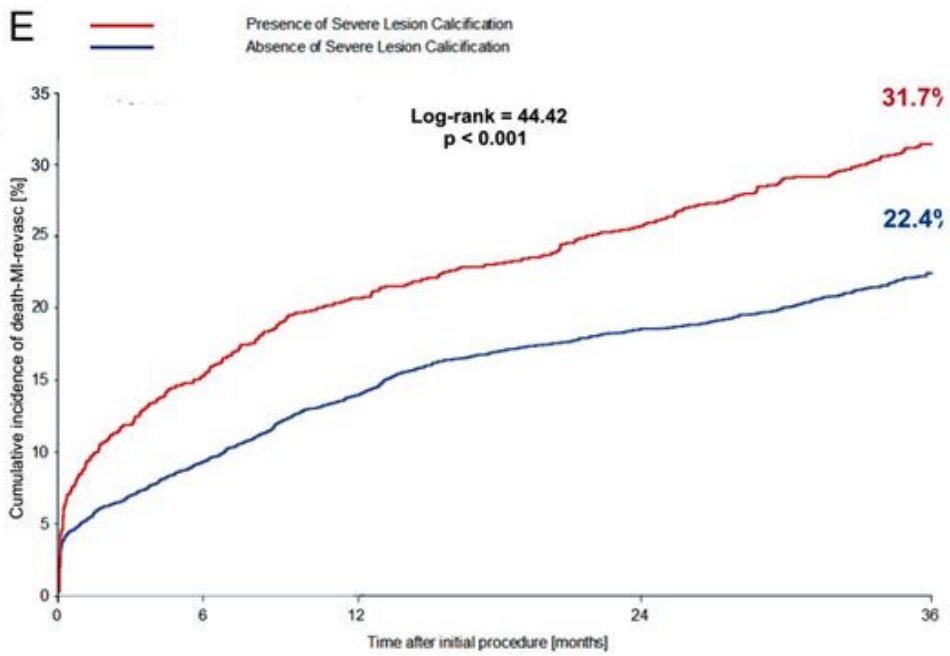

Christos V Bourantas et al. Heart 2014;100:1158-1164

Key Factors of Adequate Vessel Preparation

- **Recognize and appreciate the presence of coronary calcium and calcium burden**
  - Risk factors
  - Coronary calcium seen on chest CT
  - Angiography
    - Severe = calcium seen on both sides of the vessel without cardiac motion or >15mm in length
  - **Intravascular imaging (OCT and IVUS)**
    - Severe= >180 degrees of calcium arc, > 5 mm length, or >0.5mm thickness
- **Consider Atherectomy Strategy**
- **Ensure full balloon expansion of 1:1 sized balloon prior to stent implantation**

Adjunct Devices to Pretreat Calcium

Diamondback 360

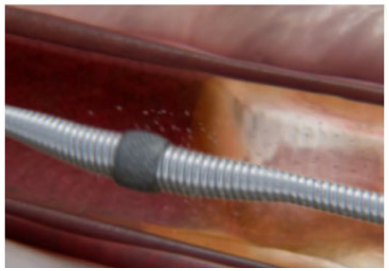

Rotablator



Laser

Scoring Balloons

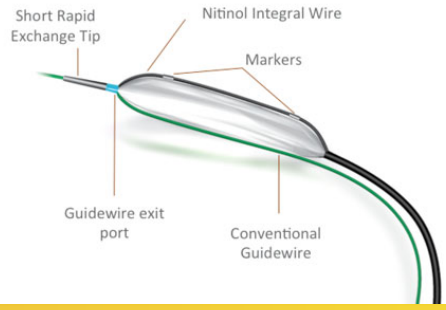

Shockwave (Lithotripsy)

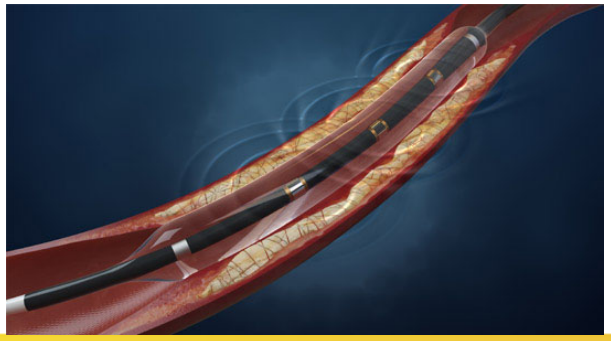

Complications associated with vessel preparation

- In adequate preparation (under-expansion)
- Dissection
- Perforation
- Distal Embolization (slow flow/no reflow)

Distal Embolization
Slow Flow/No Flow post Atherectomy

- Slow flow (TIMI 1-2) and No flow (TIMI 0) are observed in 5% of patients undergoing atherectomy
- Likely caused by obstruction of microvascular by microparticles (< 5 microns)
- Increased risk with bulky Ca or long Ca lesions
- Increased risk in patients with low EF

PCI Outcomes with Rotational Atherectomy based on LVEF

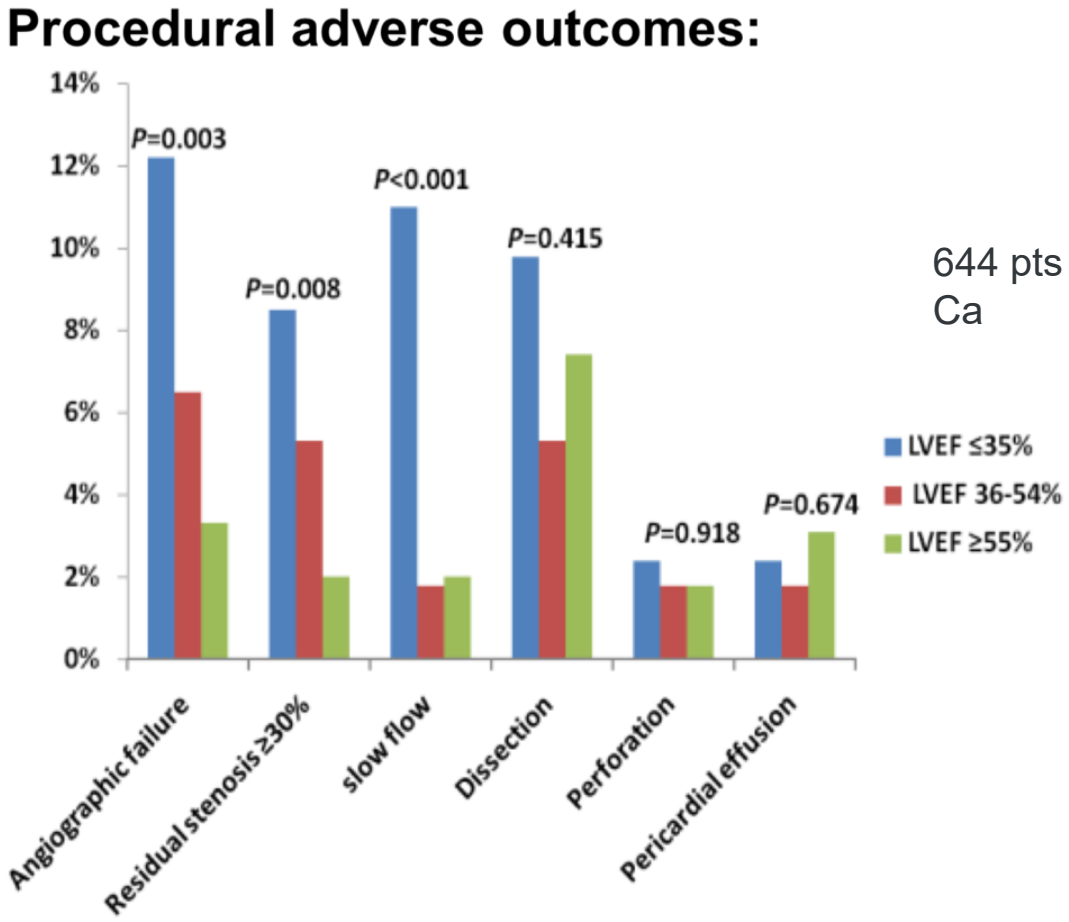

644 pts with severe Ca

Mankerious et al. Euro PCR 2019

PCI Outcomes with Rotational Atherectomy based on LVEF

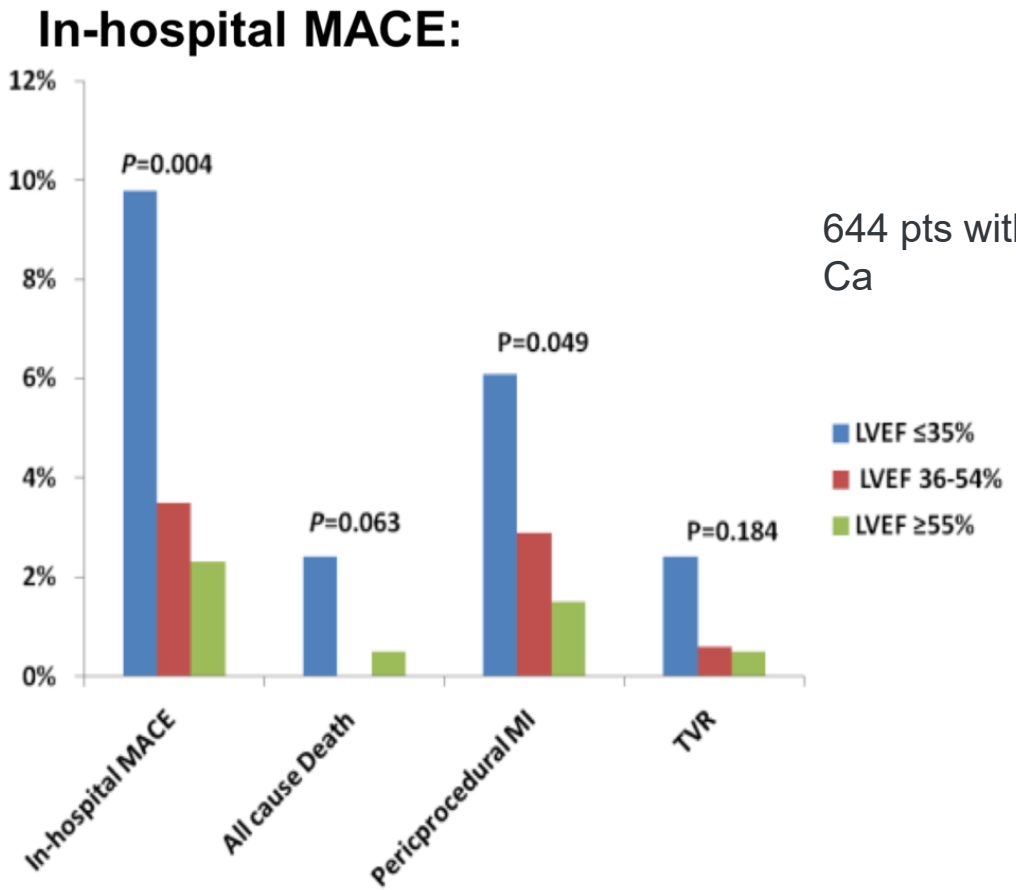

644 pts with severe Ca

Mankerious et al. Euro PCR 201

ORBIT II: Severe Angiographic Complications

Criteria	Prior to OAS	Post OAS	Post Balloon/Stent	Unknown	Overall N=443
Subjects with severe angiographic complications					7.2%
Dissection Type C- F	0.2%	2.3%	0.9%	0.0%	3.4%
Perforation	0.0%	0.9%	0.9%	0.0%	1.8%
Persistent slow flow/no reflow	0.2%	0.2%	0.5%	0.0%	0.9%
Abrupt closure	0.2%	0.9%	0.2%	0.5%	1.8%

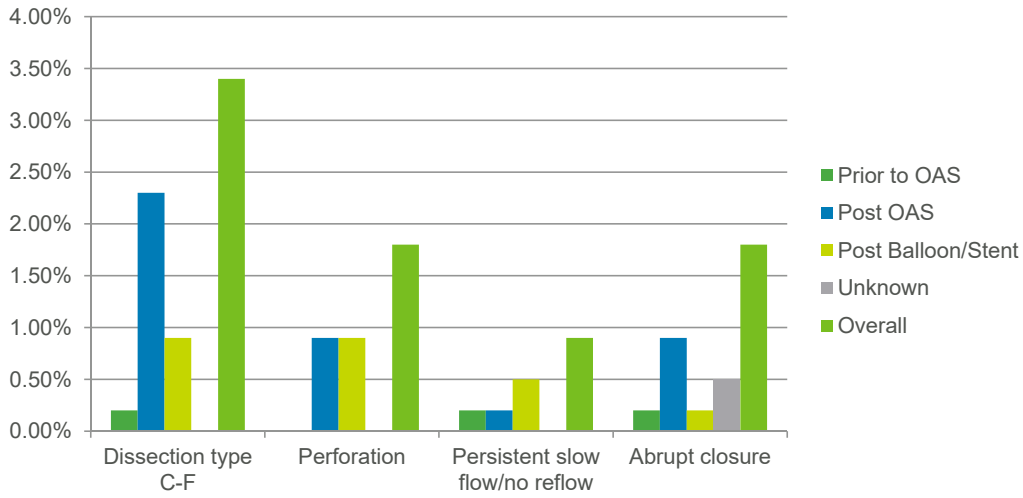

Chambers JW, et al. JACC Cardiovasc Interv. 2014;7:510-8.

ORBIT II Angiographic Complications within Range of Rotablator Literature (RA)[1*]

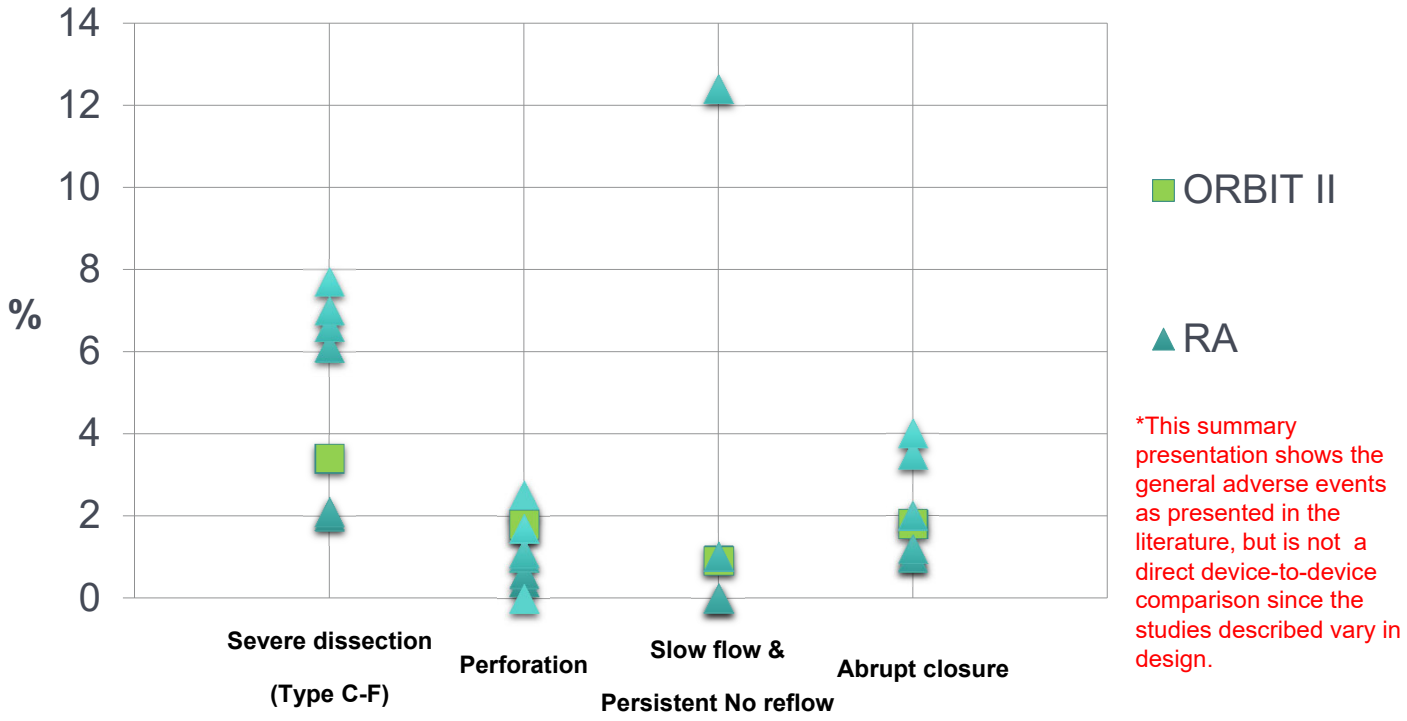

*This summary presentation shows the general adverse events as presented in the literature, but is not a direct device-to-device comparison since the studies described vary in design.

1. RA References: Abdel-Wahab (2013), Bersin (1999),Brown (1997),Clavijo (2006), Furuichi (2009), Garcia de Lara (2010), Henneke (1999), Levin (1998), Mauri (2003), Rathore (2010), Reisman (1997), Tsubokawa (2003). Note: some references did not report all complications in scatter plot.

Real-World Multicenter Registry of Patients with Severe Coronary Artery Calcification Undergoing OA*

To evaluate orbital atherectomy (OA) in real-world patients with severe coronary artery calcification (CAC)

- Retrospective, multi-center registry at 3 U.S. Sites
- 458 consecutive patients with severe CAC who underwent OA followed by stenting
- Primary Endpoint: 30-day major adverse cardiac and cerebrovascular events (MACCE), defined as all-cause death, myocardial infarction, TVR, and stroke

30-day Clinical Event Rates	n=458
MACCE	1.7%
Death	1.3%
Myocardial infarction	1.1%
Target vessel revascularization	0.0%
Stroke	0.2%

Angiographic Complications	
Perforation	0.7%
Dissection	0.9%
No-reflow	0.7%

Successful Stent Delivery	99.1%

Lee MS, et al. J Interv Cardiol 2016; 6;29:357-362

Tips for Heavily Calcified Vessels

- Be prepared- Consider Impella Support especially if:
  - Large Calcium burden
  - Long Calcified lesions
  - Reduced EF

Procedural Characteristics PROTECT III vs. PROTECT II

	All N=898	Impella CP N=571	Impella 2.5 N=327	PROTECT II Impella 2.5 N=216	p-value PROTECT III All vs P II
# Vessels Treated	2.00±0.77	2.00±0.75	2.02±0.80	1.81±0.67	<0.001
3 Vessels Treated	29.9%	28.2%	32.7%	14.4%	<0.001
LAD	37.7%	37.6%	37.9%	34.2%	0.123
Left Main	15.7%	16.8%	13.5%	11.5%	0.011
LCx	27.7%	27.1%	28.9%	28.5%	0.716
RCA	15.7%	15.3%	16.4%	19.0%	0.058
Pre-PCI TIMI 0/1	14.7%	15.7%	12.5%	7.0%	<0.001
Atherectomy Use	43.3%	45.2%	40.0%	14.2%	<0.001
# Vessels w/ Atherectomy	2.01±0.75	2.03±0.74	1.96±0.77	1.44±0.62	<0.001
Contrast Volume (mL)	204.2±105.6	206.9±105.4	199.4±106.0	267.5±141.7	<0.001
	6.79±21.1	7.78±22.3	4.83±18.2	1.9±2.7	<0.001

Popma et al, TCT 2019

PROTECT III Outcomes Compared to Protect II

Composite Major Adverse Cardiac and Cerebrovascular Events (MACCE) at 90 Days

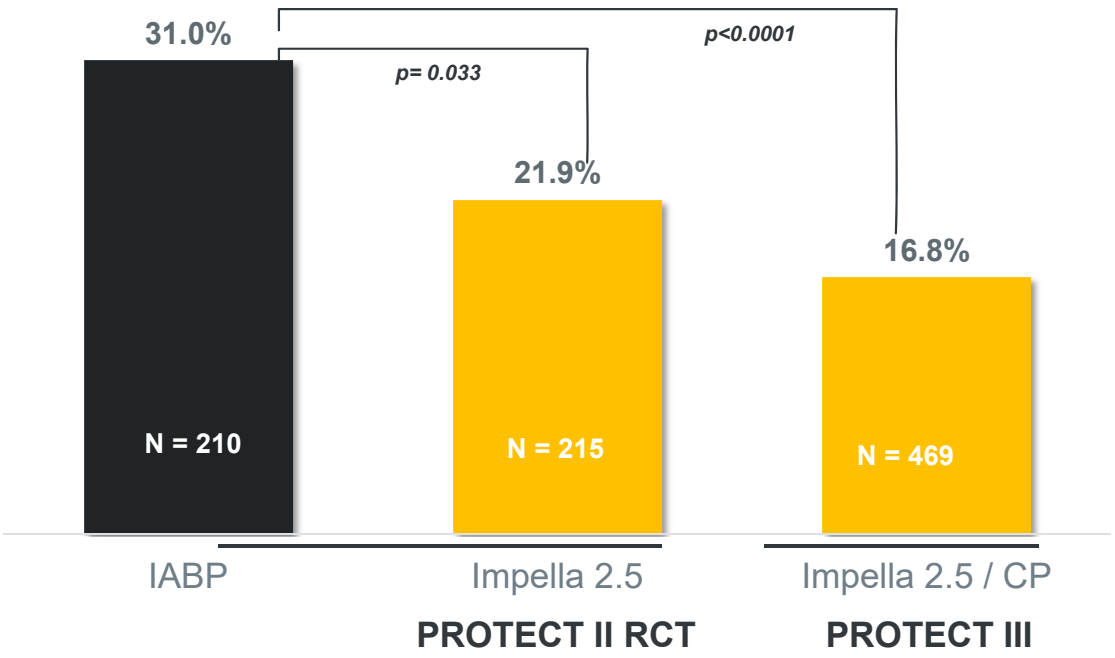

N = number of patients with 90-day follow-up

Popma et al, TCT 2019

Impella® Reduces Peri & Post Procedural MACCE

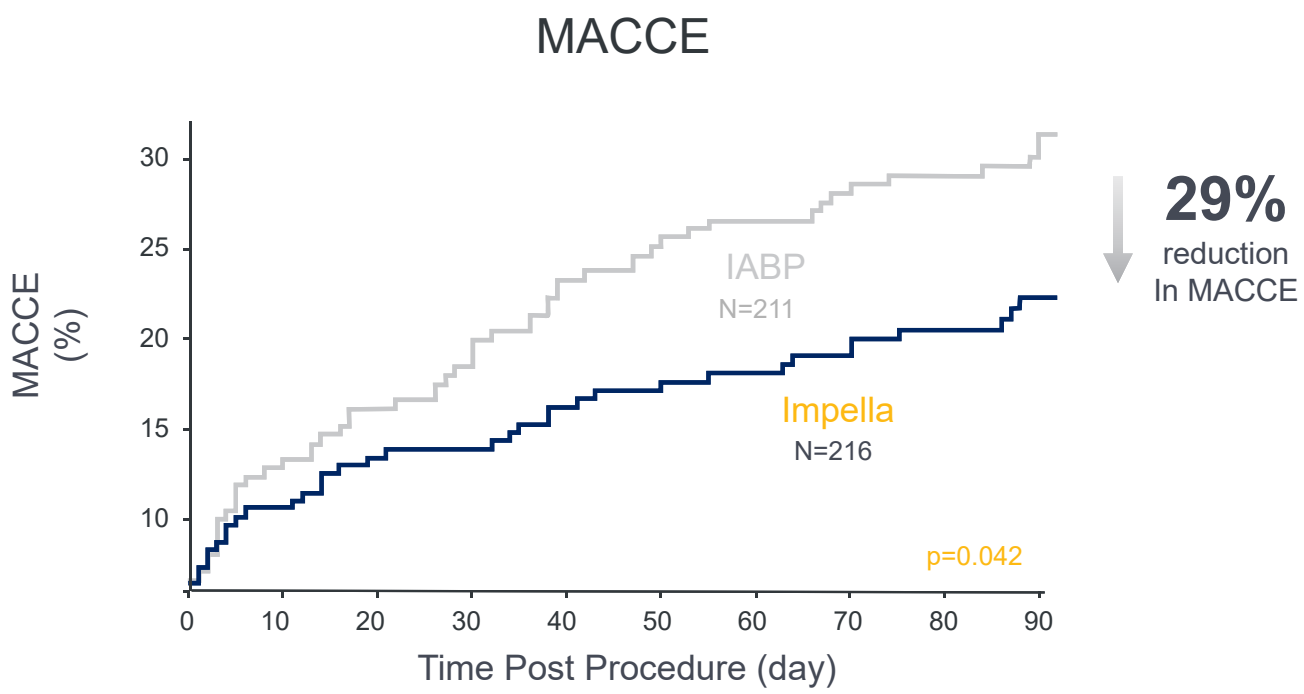

FDA Randomized Controlled Trial
Protect II

Dangas et al, Am. Journ of Cardiol. 2014: 113(2):222-8

Tips for Heavily Calcified Vessels

- Orbital Atherectomy
  - Slow advancement (<1mm/sec)
  - short runs (<20 seconds each + 20 sec pauses)
- Rotational Atherectomy
  - Avoid run lengths > 3cm
  - Avoid RPM decelerations > 5000 rpm
  - Short runs (<30 seconds each + rest in between)
  - Avoid total burr time > 5 min
  - Step up burr size as needed

Don’t Push The Device Too Fast

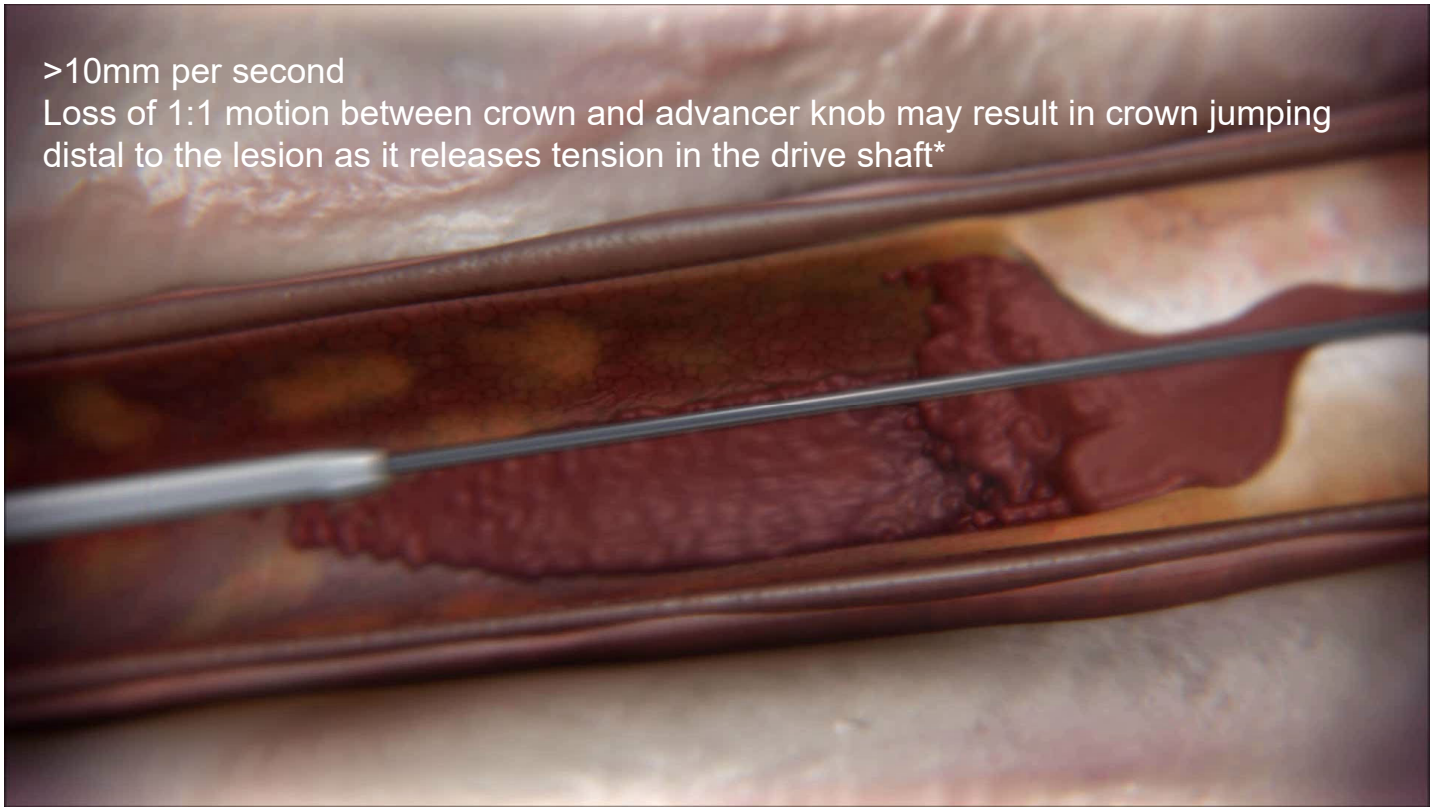

*If loss of 1:1 motion occurs, slowly retract the crown and re-engage the lesion with slow forward movement. Repeat slowly retracting and advancing the crown into the lesion until 1:1 movement is observed.

Example: Traverse Speed Too Fast: >10mm per Second

Too Fast: >10mm / Sec

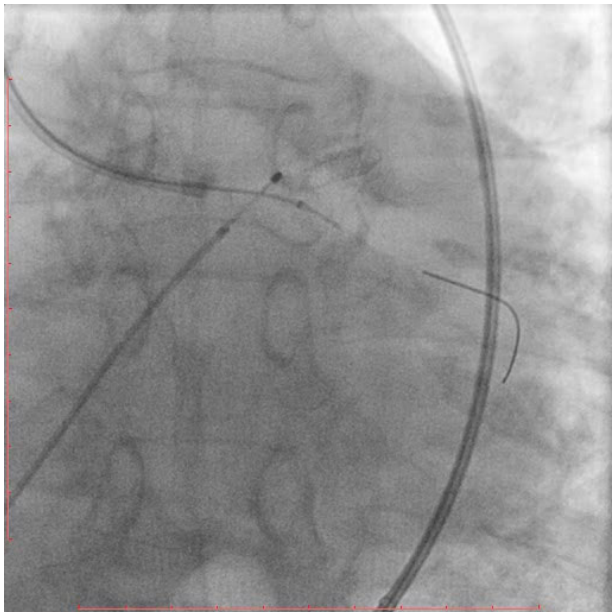

Too Fast: >10mm / Sec
Do not use pecking motion



Slowly advance and retract the crown advancer knob to begin atherectomy of the lesion at a travel rate of 1mm - 10mm per second.
If treating a tight lesion, or during initial passes of a tight lesion, advance and retract slowly to verify 1:1 movement.

Model designed to ensure jumping occurs
Automated fixture arm moving at 10mm/sec and 1mm/sec
with loss of 1:1 motion* between the advancer knob and the crown

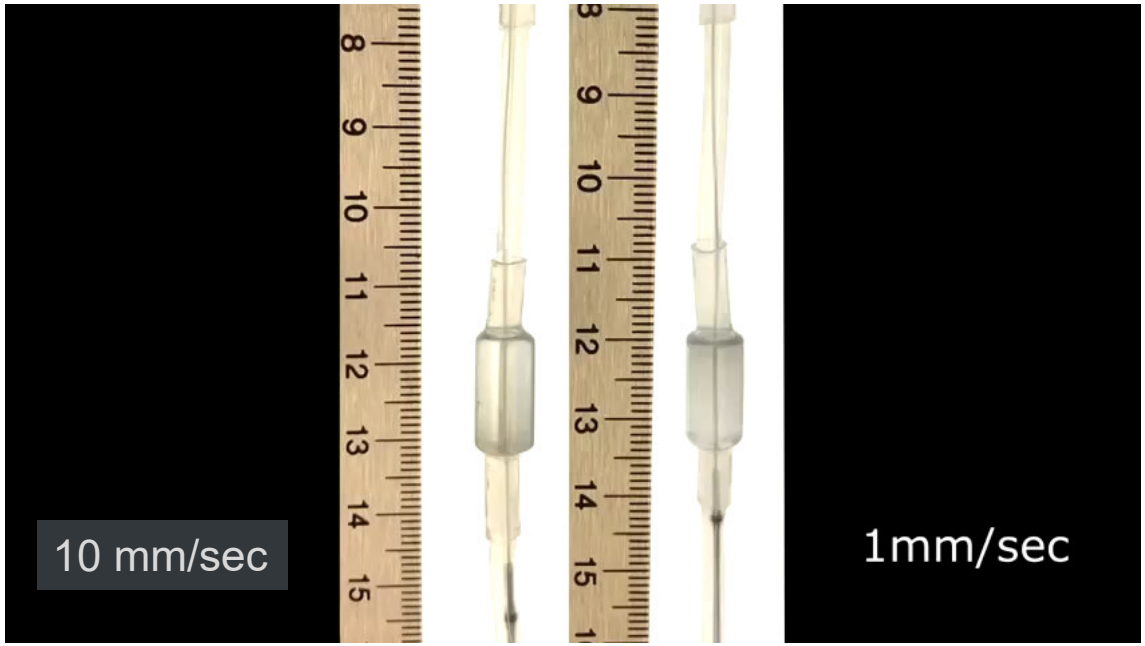

*If loss of 1:1 motion occurs, slowly retract the crown and re-engage the lesion with slow forward movement. Repeat slowly retracting and advancing the crown into the lesion until 1:1 movement is observed.

Tips for treating Calcium in Severe Tortuosity

- Be prepared- Consider Impella Support
- Use less stiff wire to limit wire bias

Rota-Floppy Wire

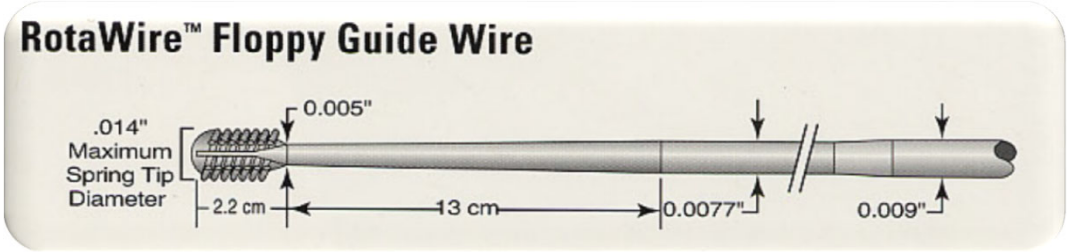

- Flexible and torqueable to enhance navigation
- Significantly reduced guidewire bias
- Short Spring Tip (2.2 cm)
- Light rail support

Tips for treating Calcium in Severe Tortuosity

CSI ViperWire Advance

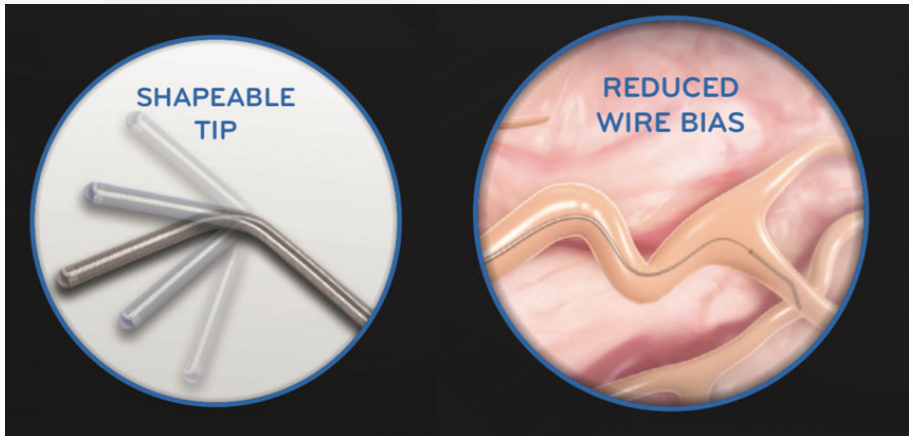

Tips for treating Calcium in Severe Tortuosity

- **Rotational Atherectomy**
  - Avoid burr runs in areas of wire bias

- **Orbital Atherectomy**
  - If calcified plaque on Outer curvature
    - Spin while advancing to favor outer curve



  - If calcified plaque on Inner curvature
    - Use Glide-assist to go past lesion in tortuous area and spin while pulling backwards to favor inner curve

High Speed Video in a Curved Tube



Coronary Wire Bias Illustration



Lessons Learned

CASE #1 – Tortuous Calcified Circumflex

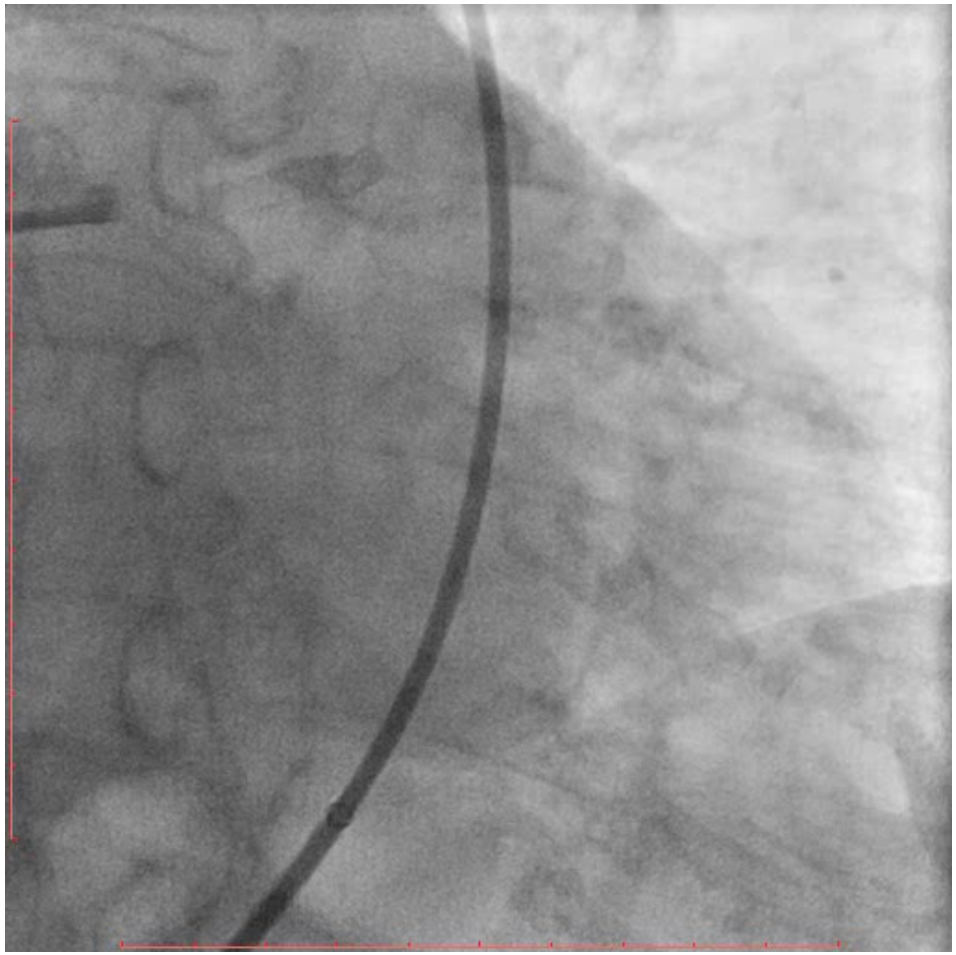

Device: Traverse Speed to Rapid
Wire: Too Close for Comfort

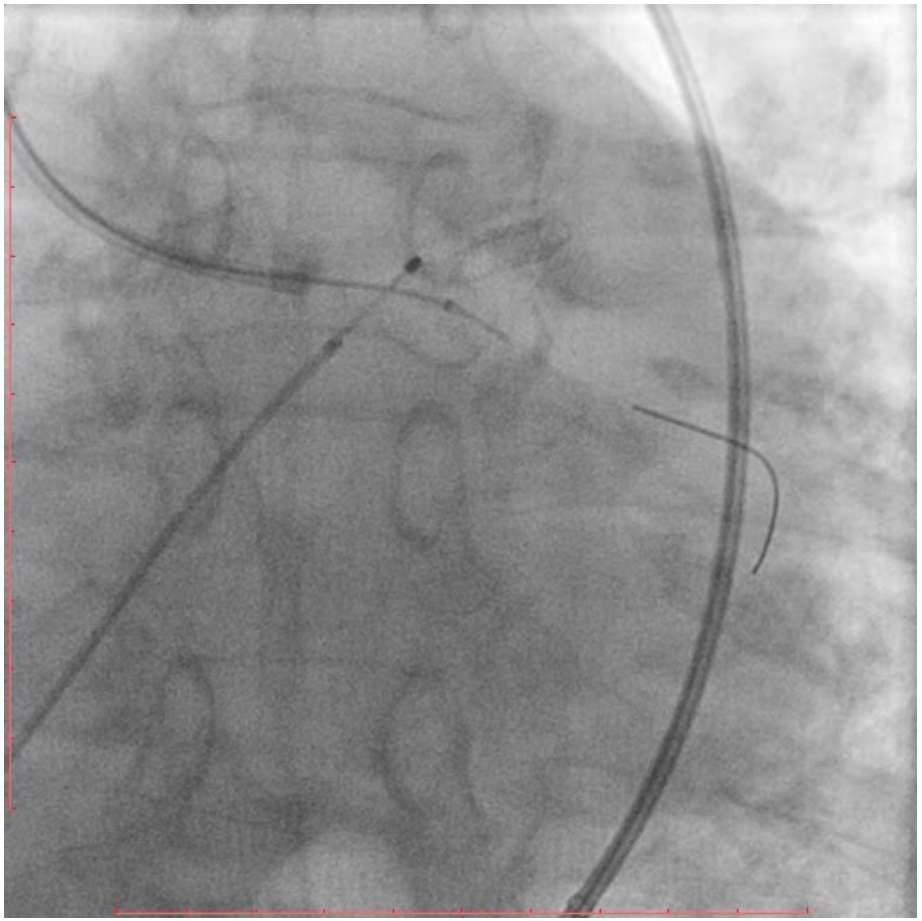

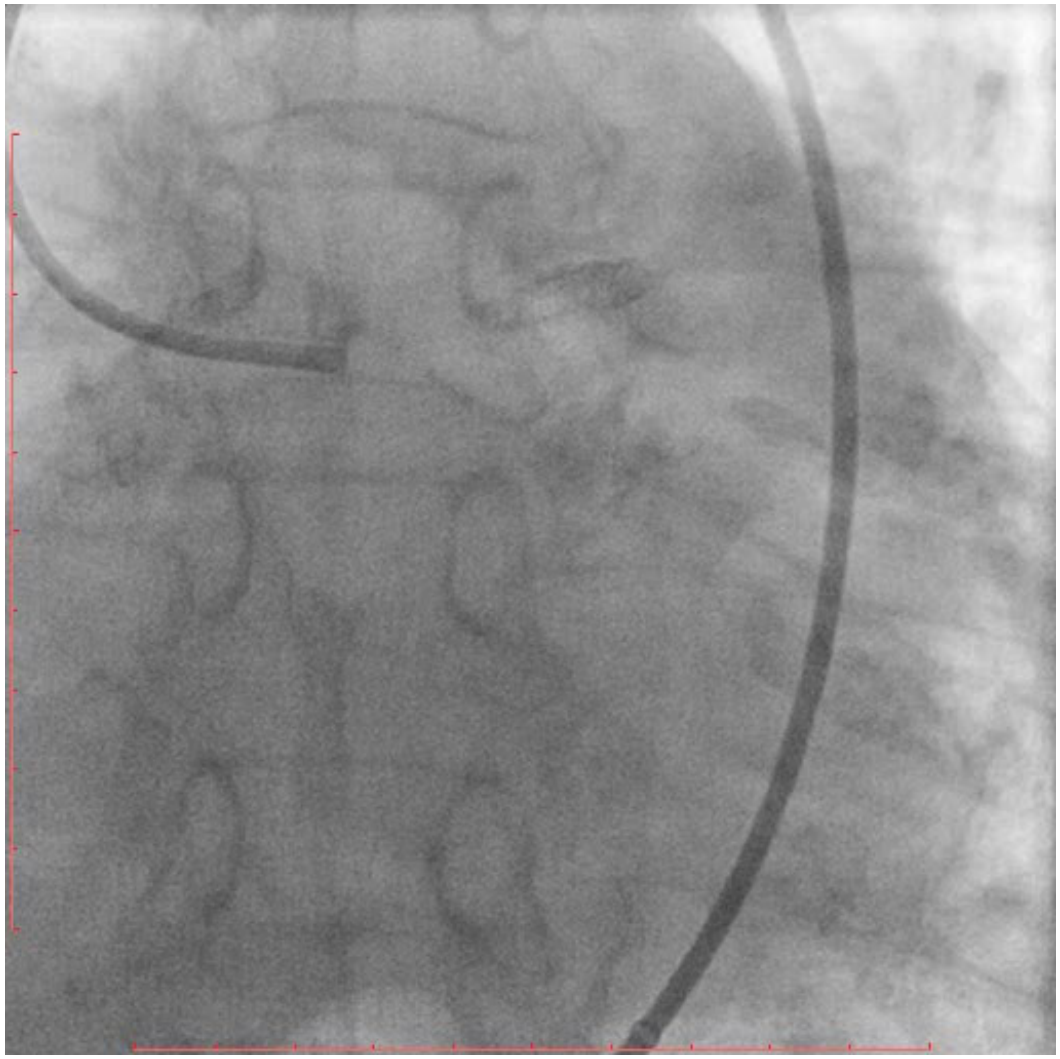

Perforation Sealed

Be Mindful of Distal Wire Position at all Times During Procedure

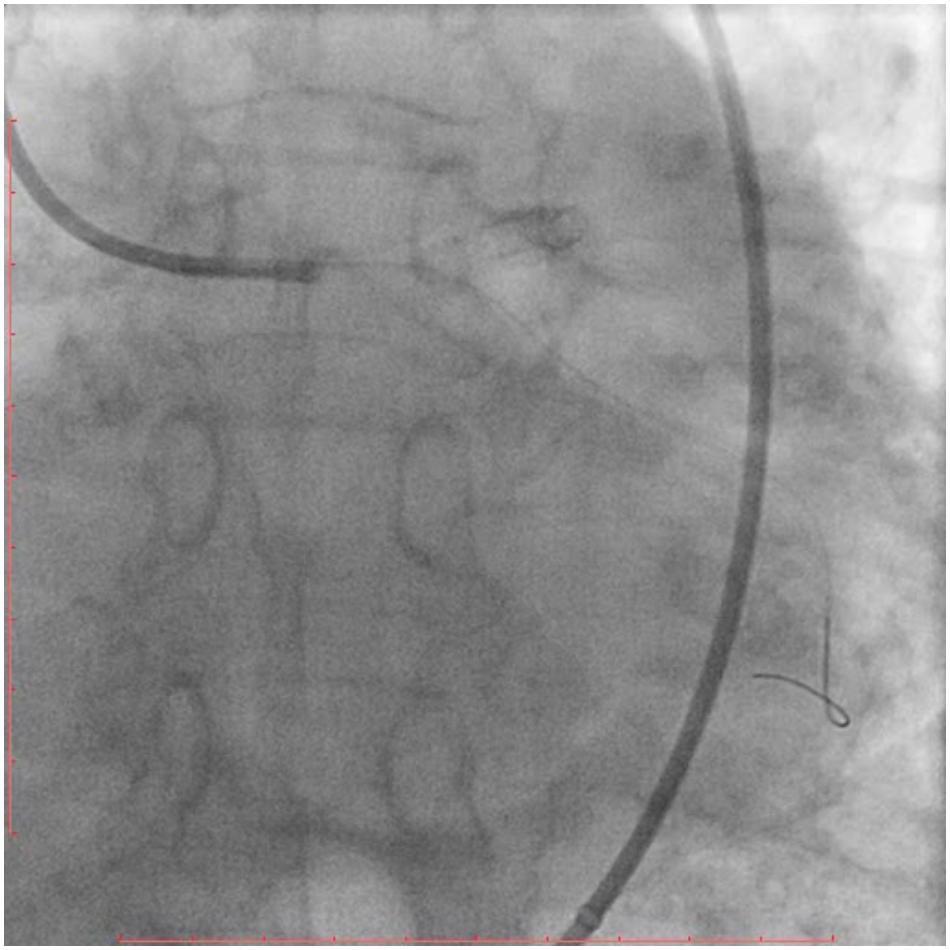

Case 2: Ostial RCA

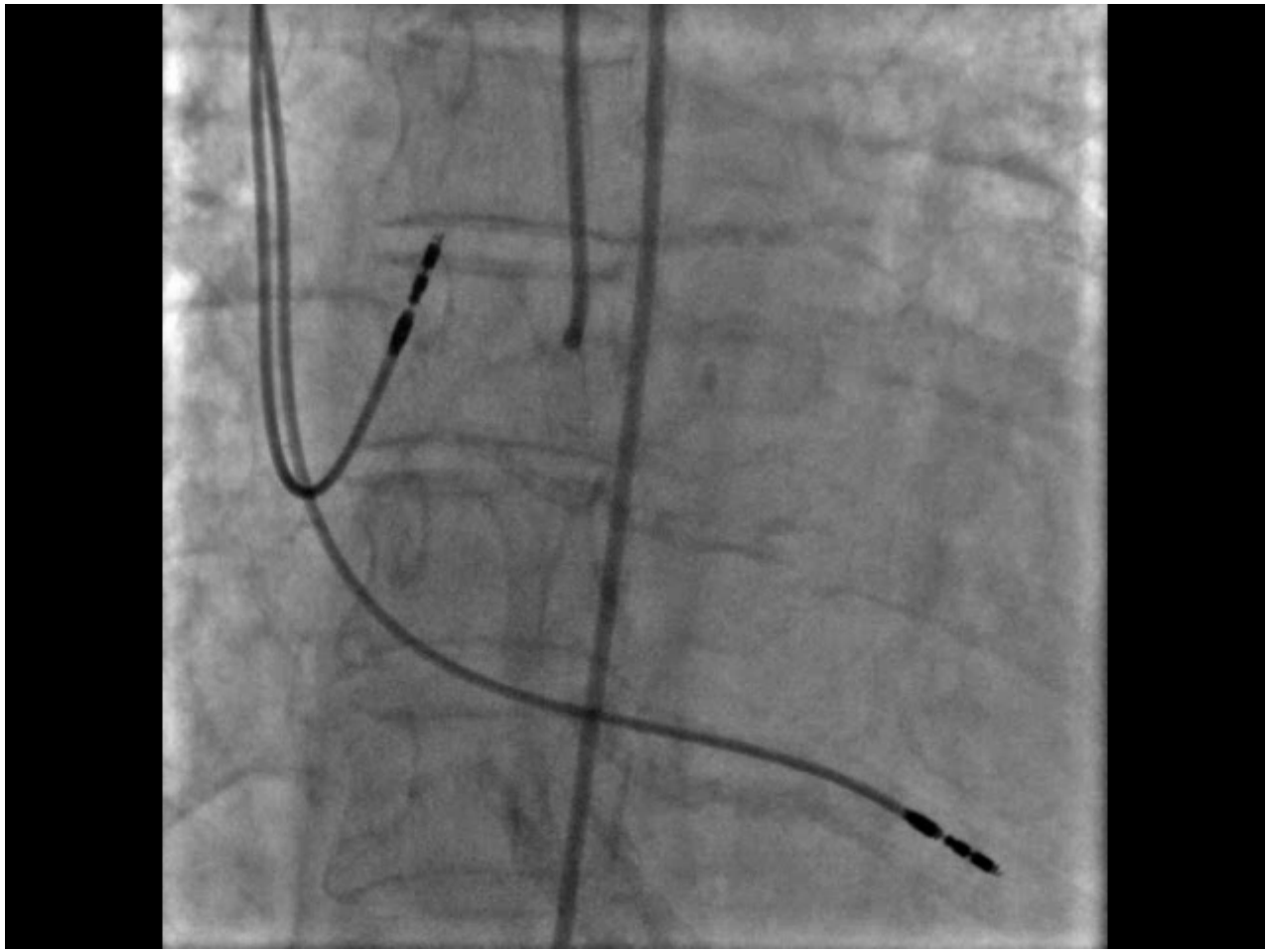

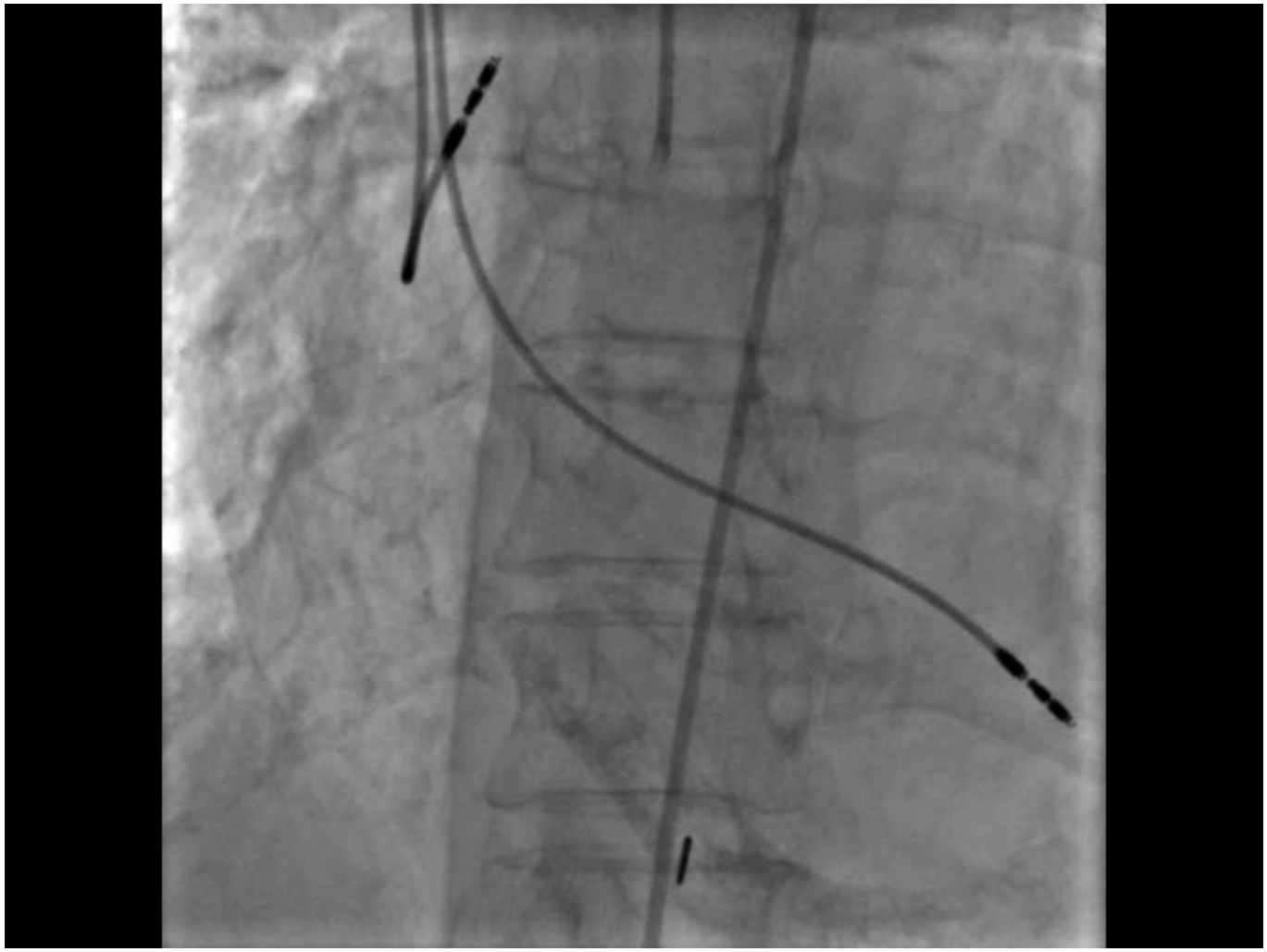

Learning Points

1. Calcified ostial rights are prone to dissection/perforation even with balloon pre-dilation
2. Consider allowing the tip of the device to enter the ostium prior to spinning to constrain the orbit.
3. Guide catheters need to be coaxial to avoid shear force against the wall.
4. Slow speed during atherectomy
5. Consider retrograde atherectomy if using CSI

Case 3 -tortuosity

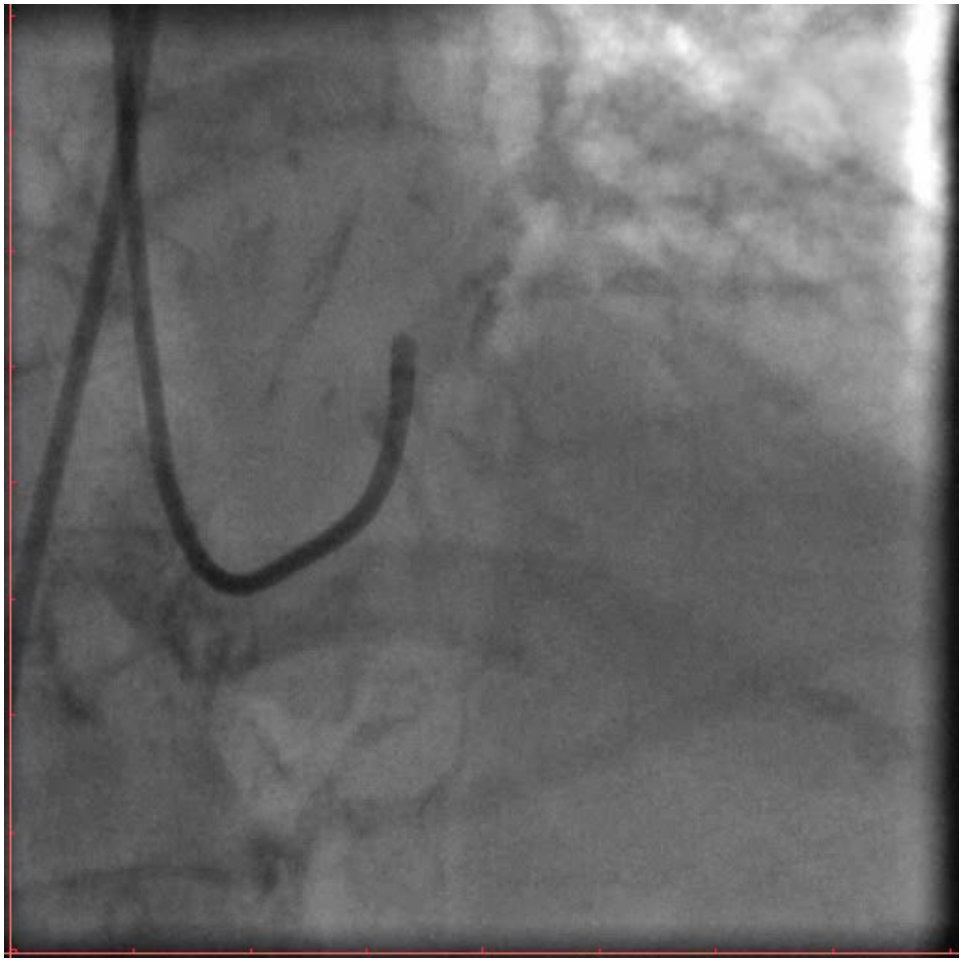

Difficult Lesion to Wire

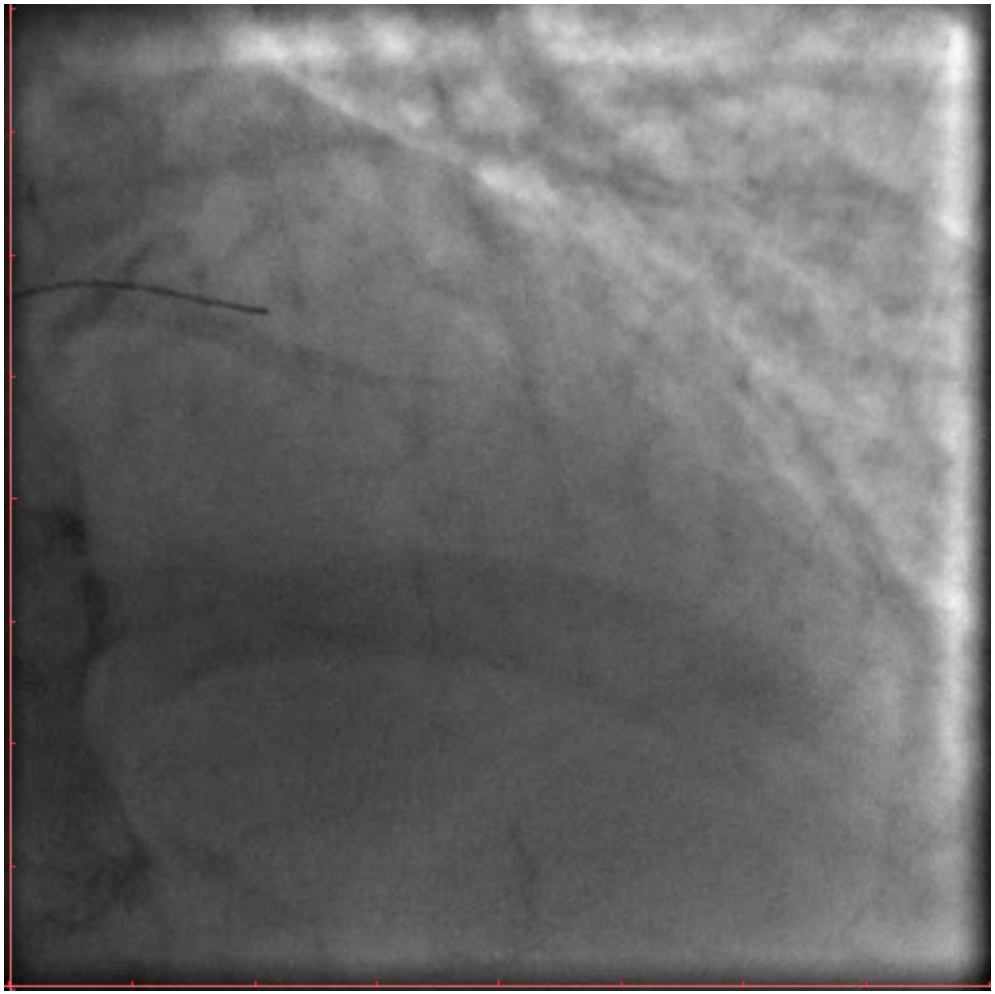

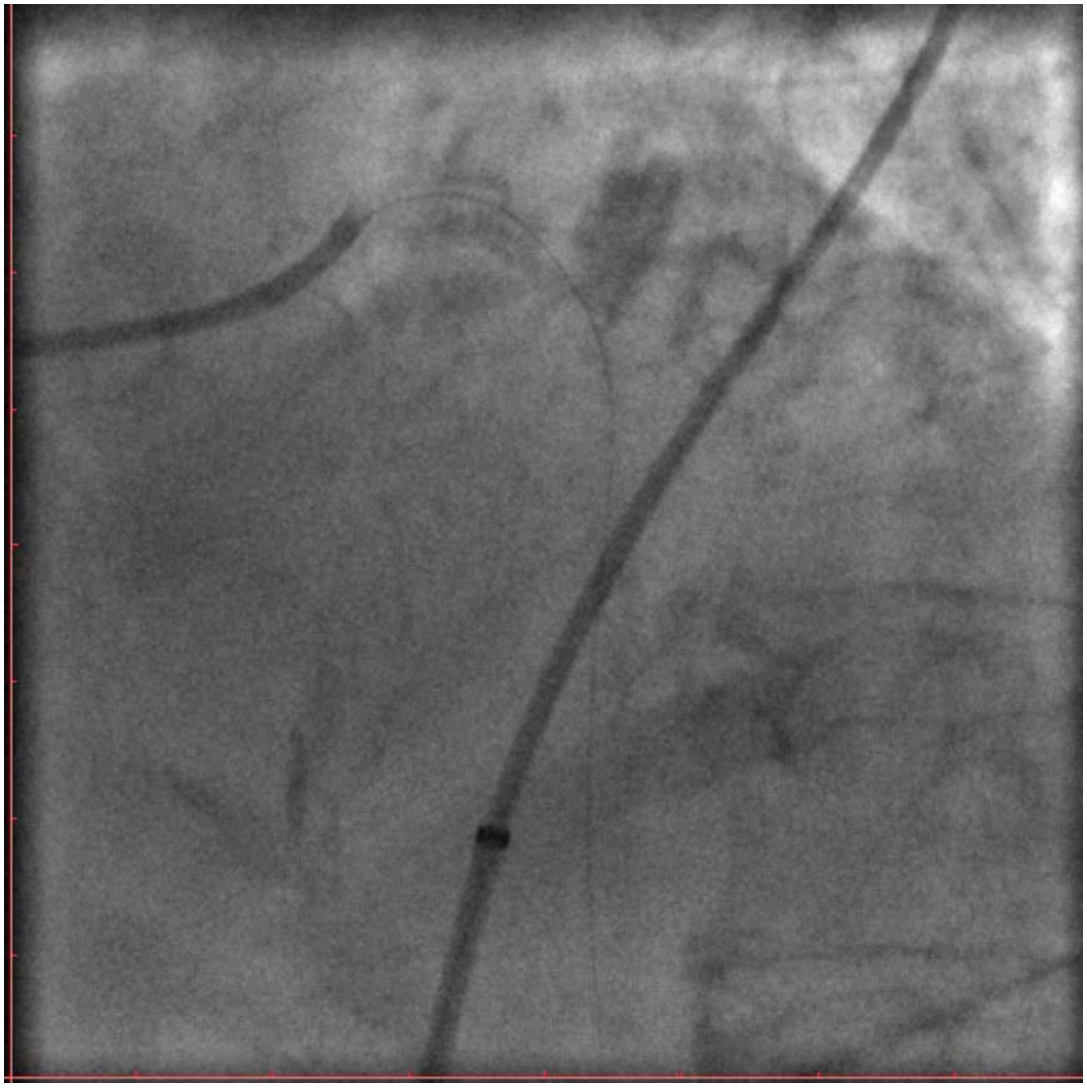

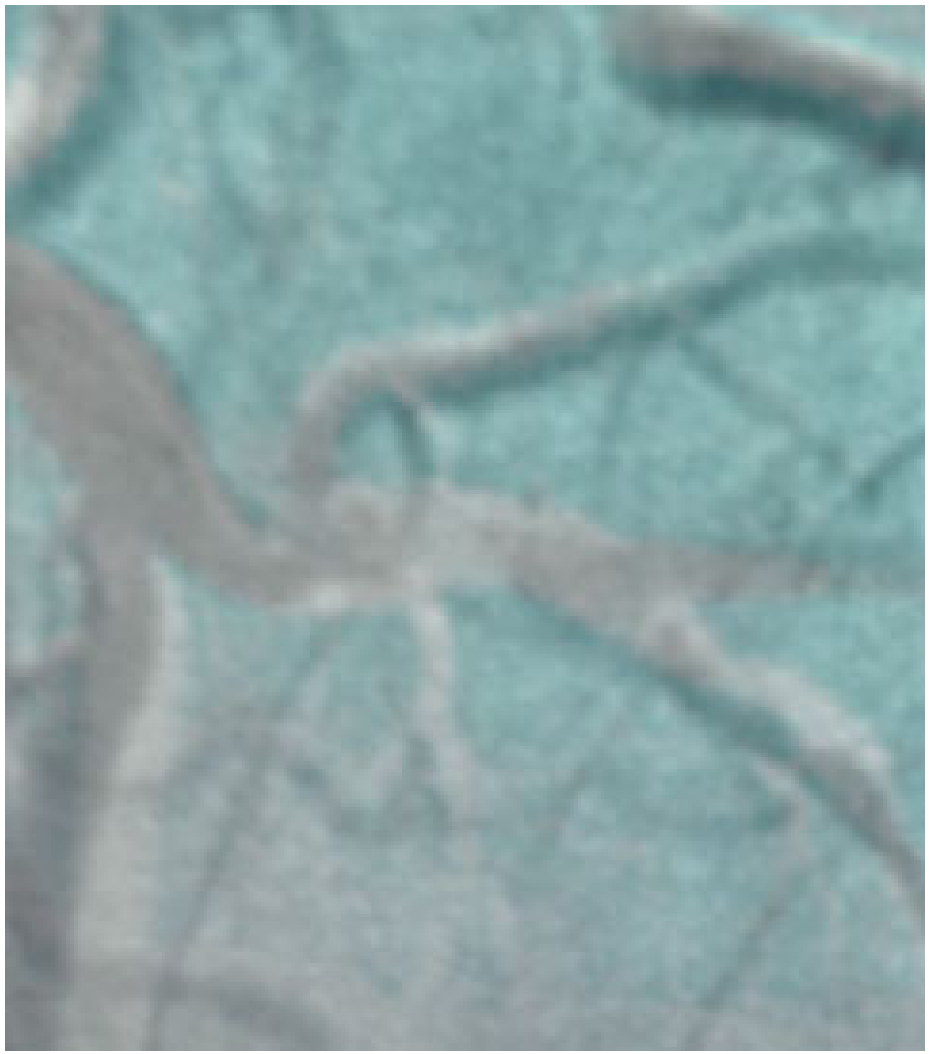

CASE 4 - Severe Tortuosity

- 76 yo male with 1 year worsening chest pain
- PMH
  - DM, HTN, Hyperlipidemia
  - CAD prior stenting LAD
  - 1v CABG to RCA, subsequently occluded
  - Failed PCI attempt x 2 of tortuous RCA- POBA with 2.0 balloon only, now worsening chest pain

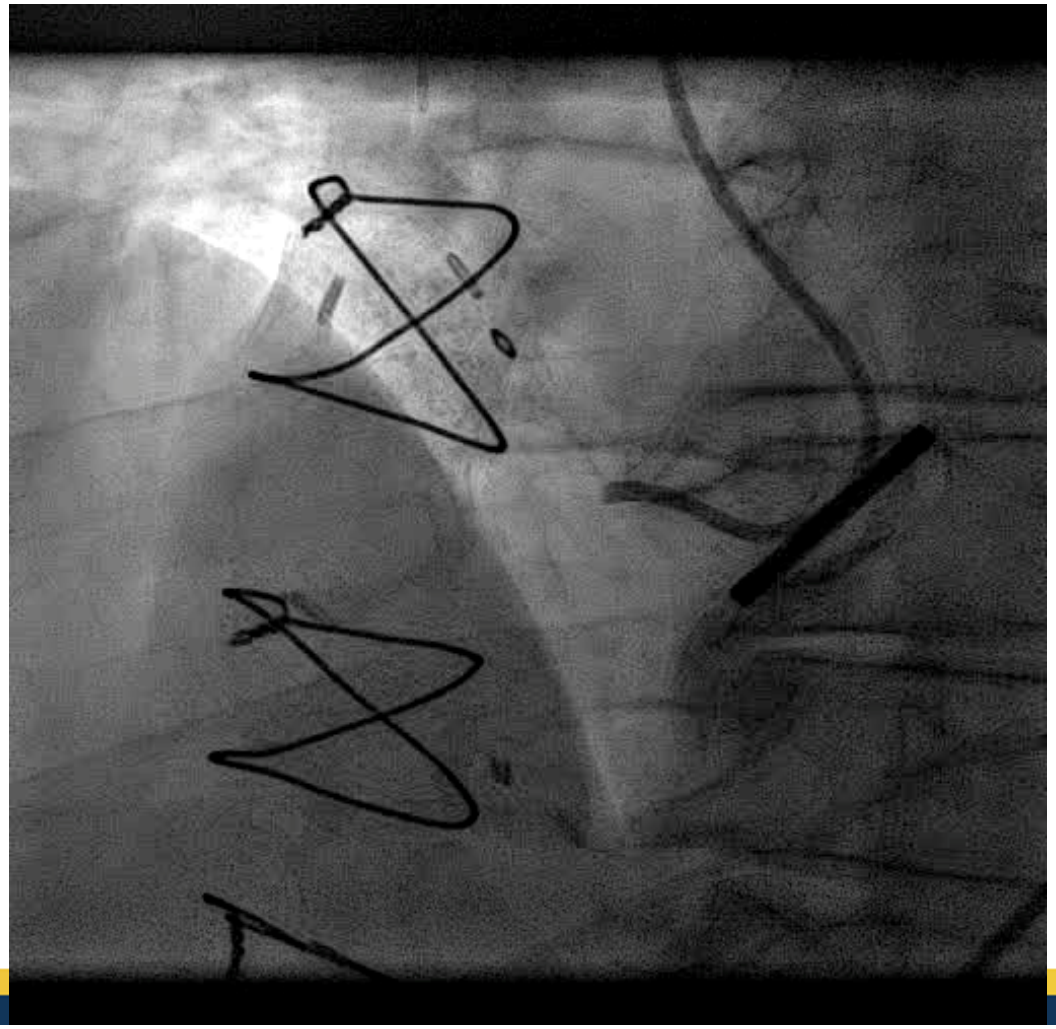

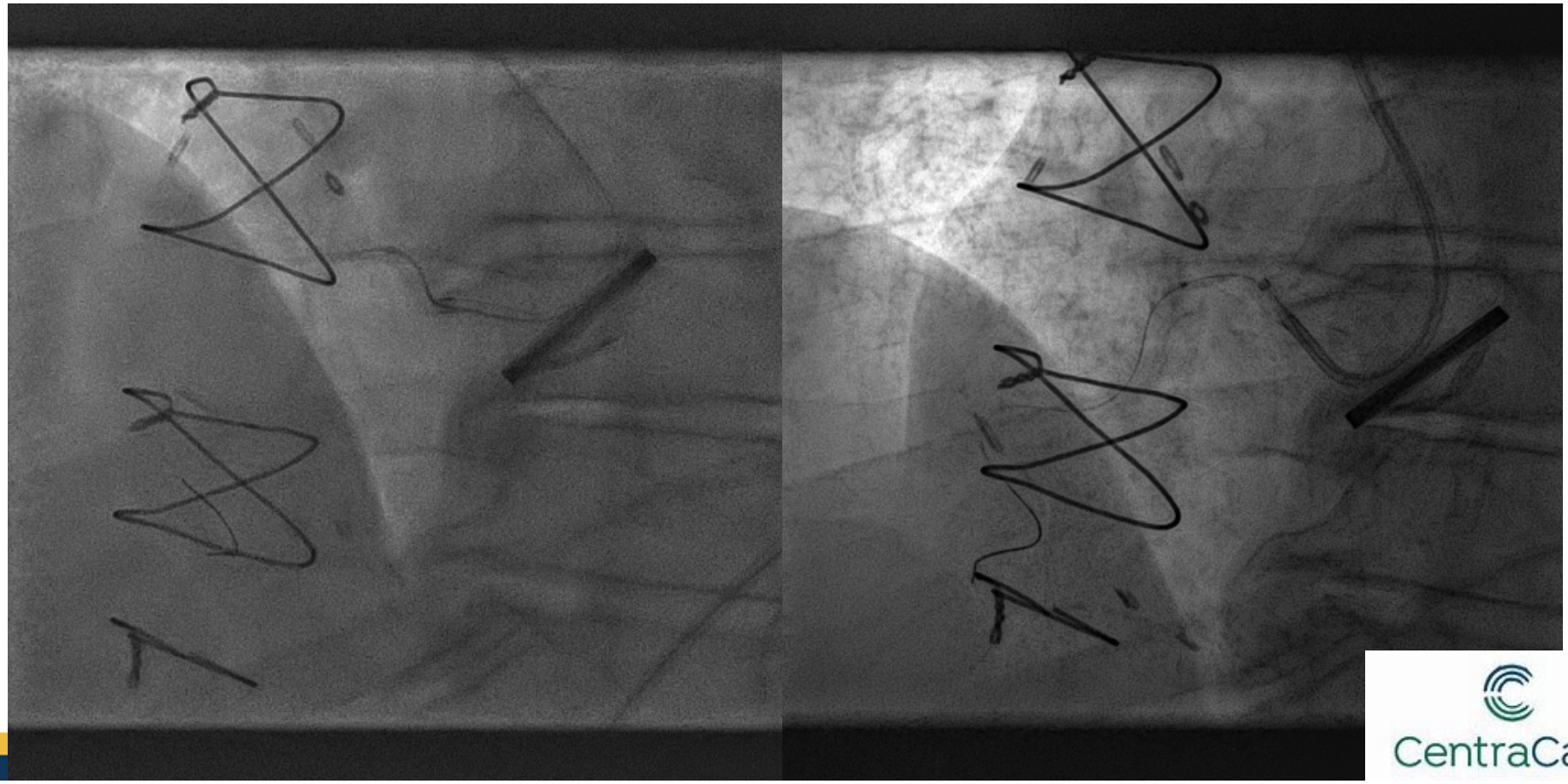

CAMP PCI
Coronary Artery & Myocardial Protected

CentraCare™

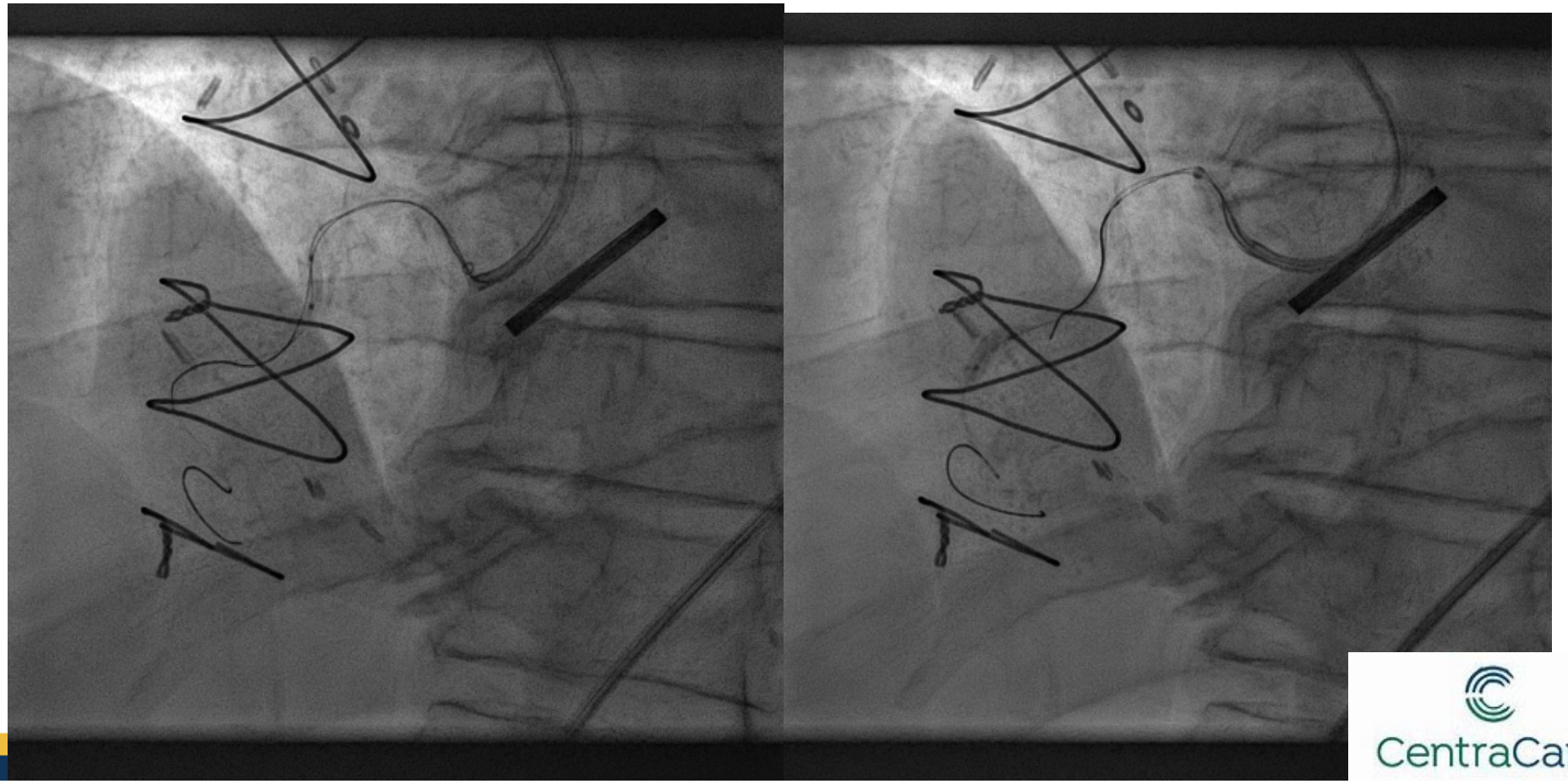

CAMP PCI
Coronary Artery & Myocardial Protected

CentraCare™

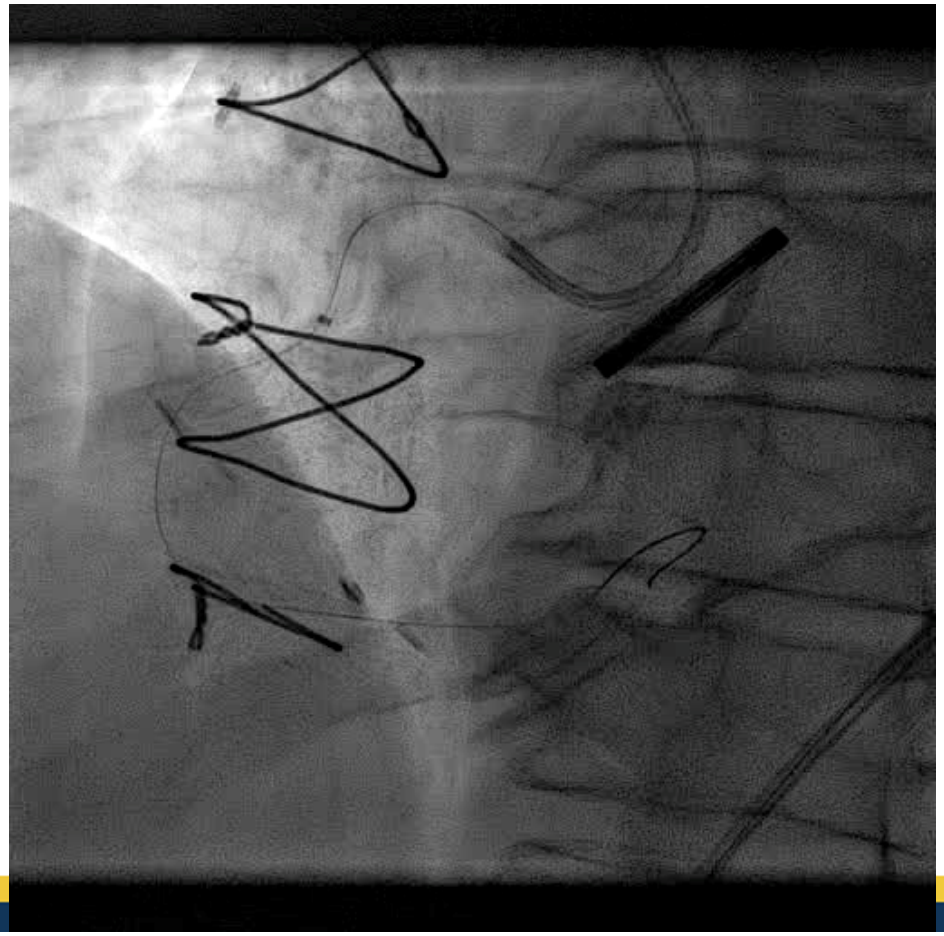

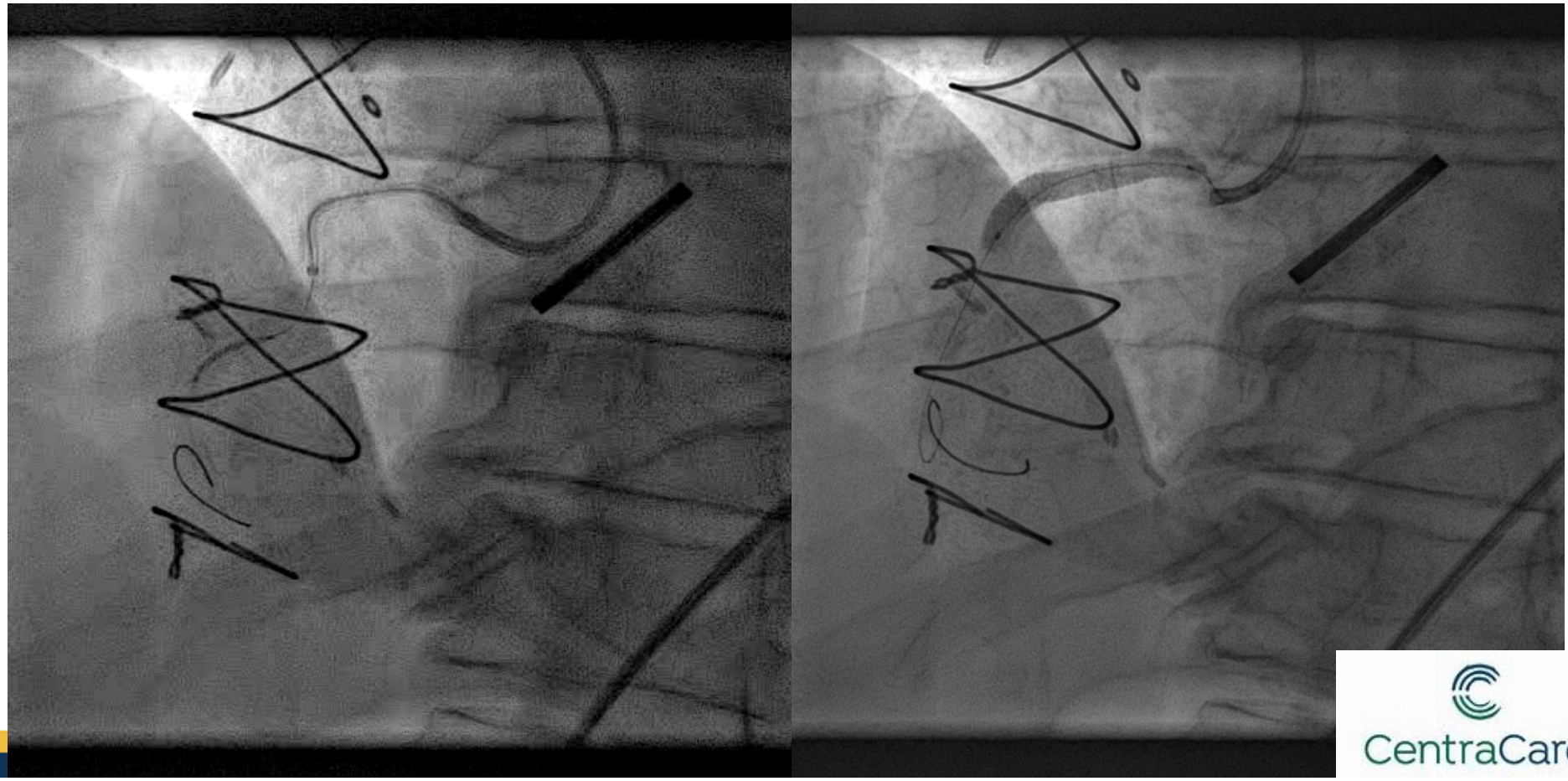

CAMP PCI
Coronary Artery & Myocardial Protected

CentraCare™

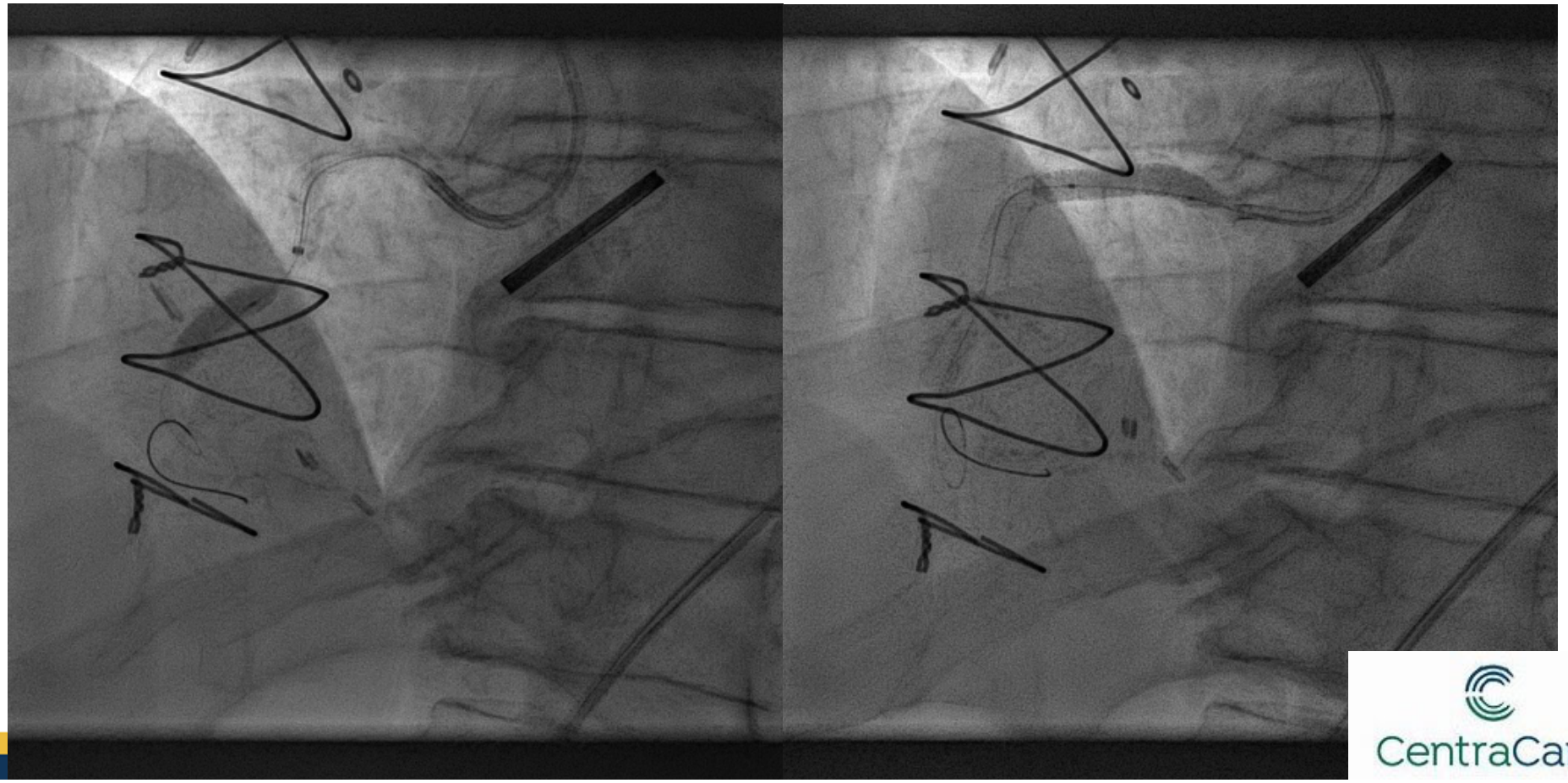

CAMP PCI
Coronary Artery & Myocardial Protected

CentraCare™

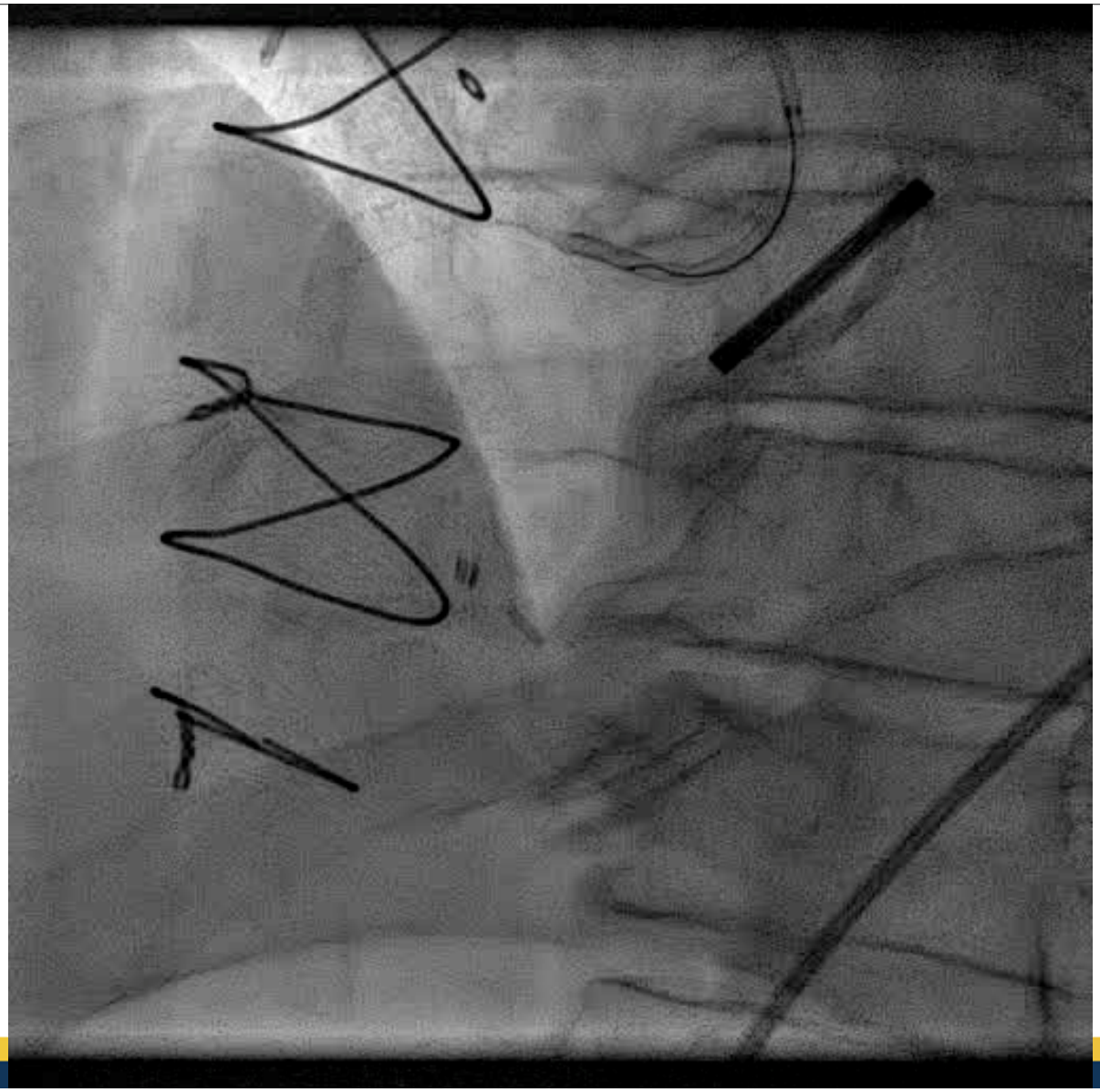

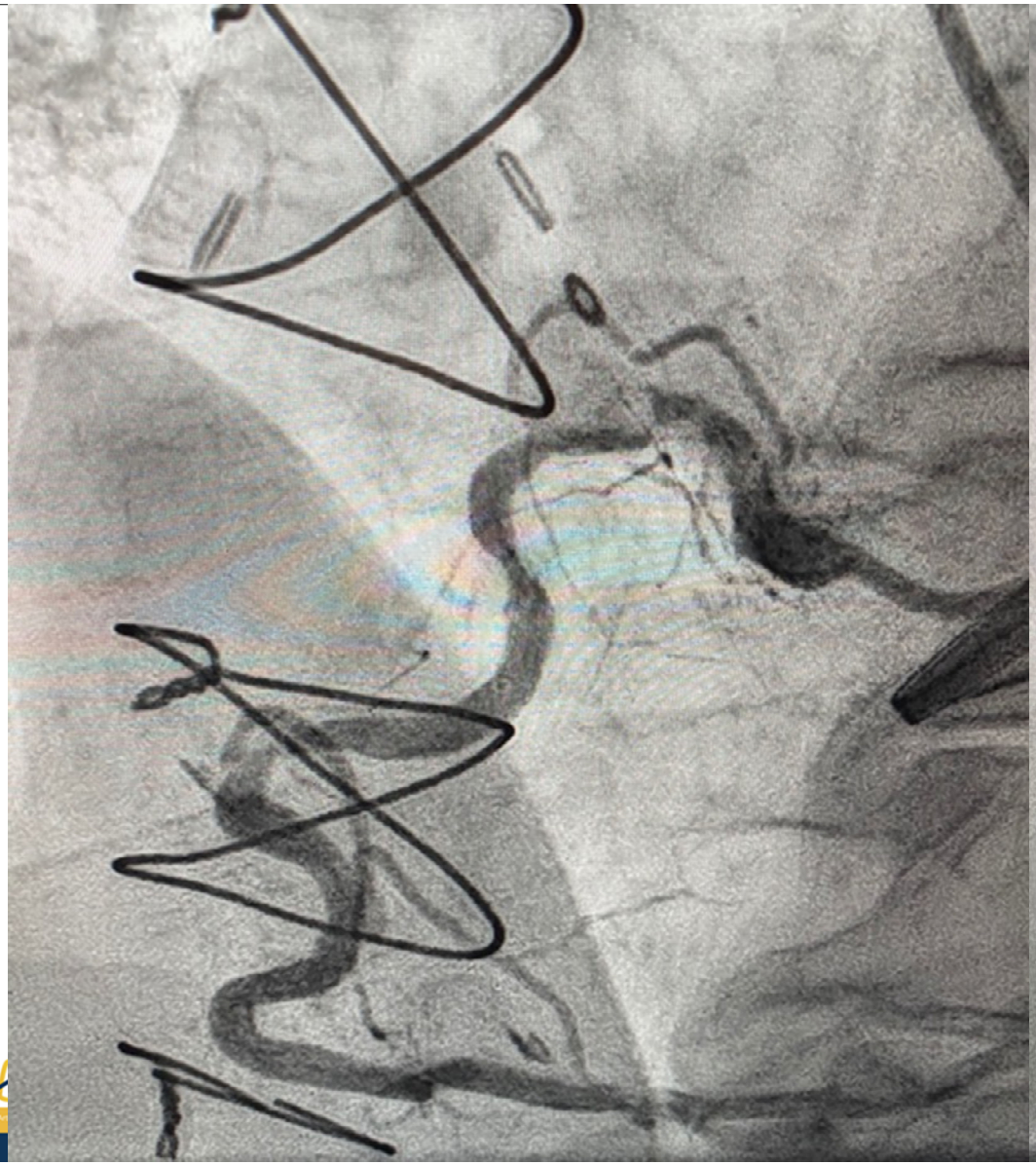

CentraCare™

CASE 4 - Follow-up

- Discharged same day (per COVID precautions)
- 1 week video follow-up- CP completely resolved (previously daily x 1 year)

CASE 5 - 71 yo male with progressive Jaw pain x 1 mo, now 10 sl nitro/day x 1 week

- ESRD stage not on dialysis Cr 3.8
- DM-II
- Hypertension
- Hyperlipidemia
- Severe peripheral vascular disease
- Known multivessel CAD
  - Inferior STEMI non-dom RCA 2000 – POBA
  - PCI of left PDA 2003
  - PCI OM2 and POBA left PDA 2013
  - PCI LAD and left PDA 2017
  - PCI mLAD, left PDA and OM2 2019
  - TAVR Oct 2019 with 26 mm Edwards Sapien 3 valve from left axillary artery given his PVD

Echo on admission

- Left ventricular systolic function is mildly decreased (EF 45-50%)- previously 65% 12/3/19
- A 26 mm Edwards SAPIEN 3 valve is present, mean gradient of 7.24 mmHg. There is no aortic regurgitation.

Coronary Angiogram

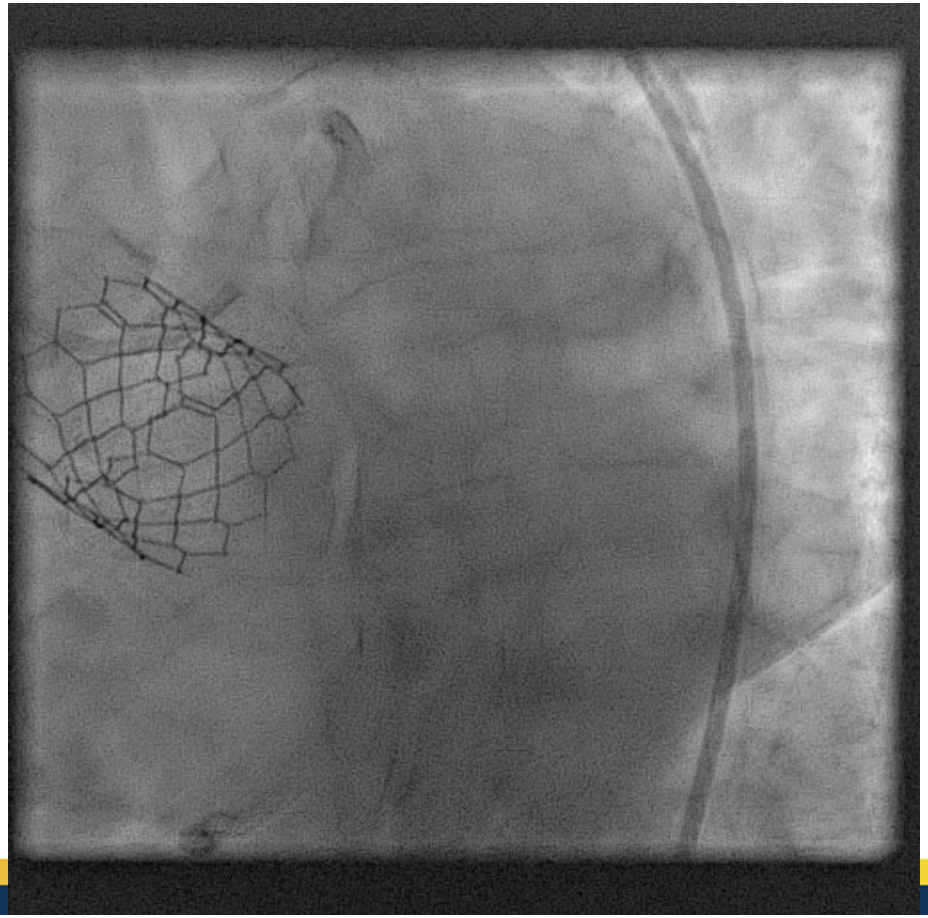

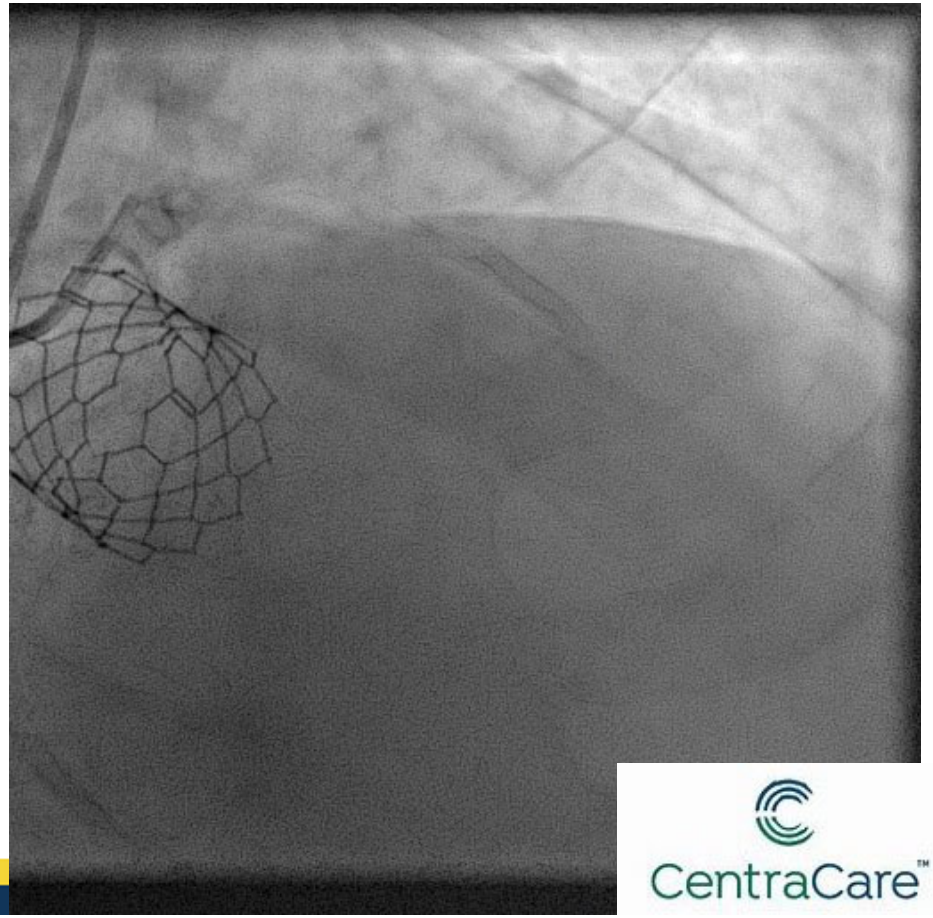

CAMP PCI
Coronary Artery & Myocardial Protected

CentraCare™

Coronary Angiogram (Pre TAVR 2019)

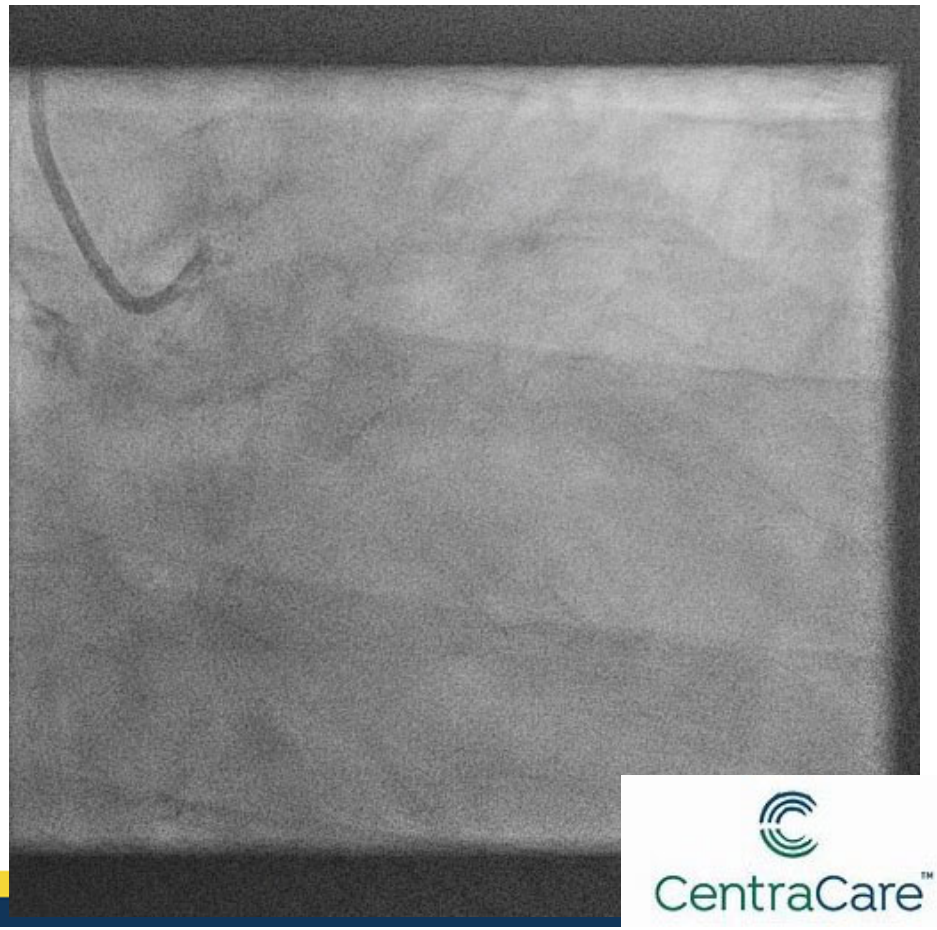

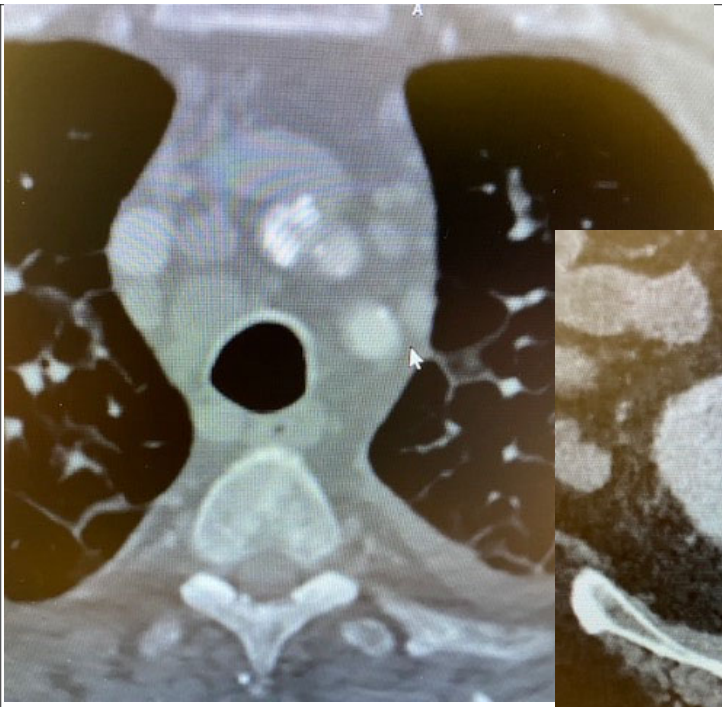

Access

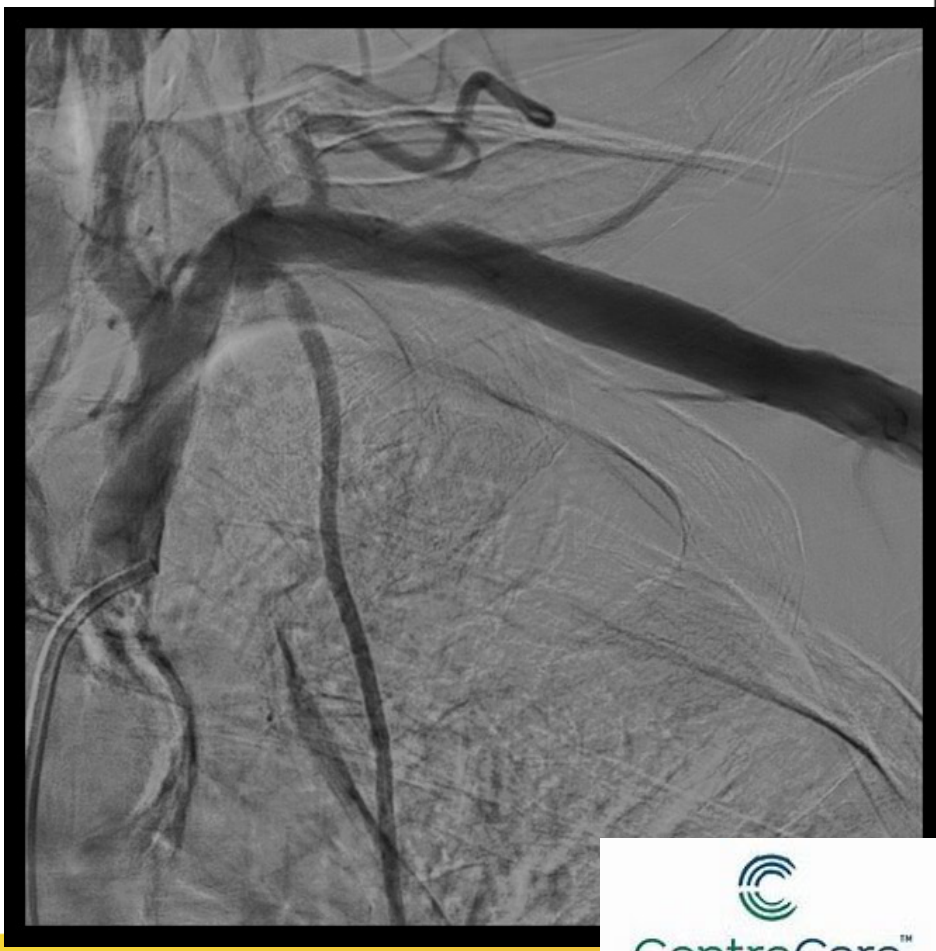

CAMP PCI
Coronary Artery & Myocardial Protected

CentraCare™

Plan

- Left Perc Ax Impella Support
- Limited contrast (Goal <30cc)
- CSI Lmain to LAD, pLCx, mLCx
- Coulotte Lmain to LCx, then LAD, and mid LCx stent to limit contrast
- Oh and lets do it as our live case this week ……

Pre no contrast

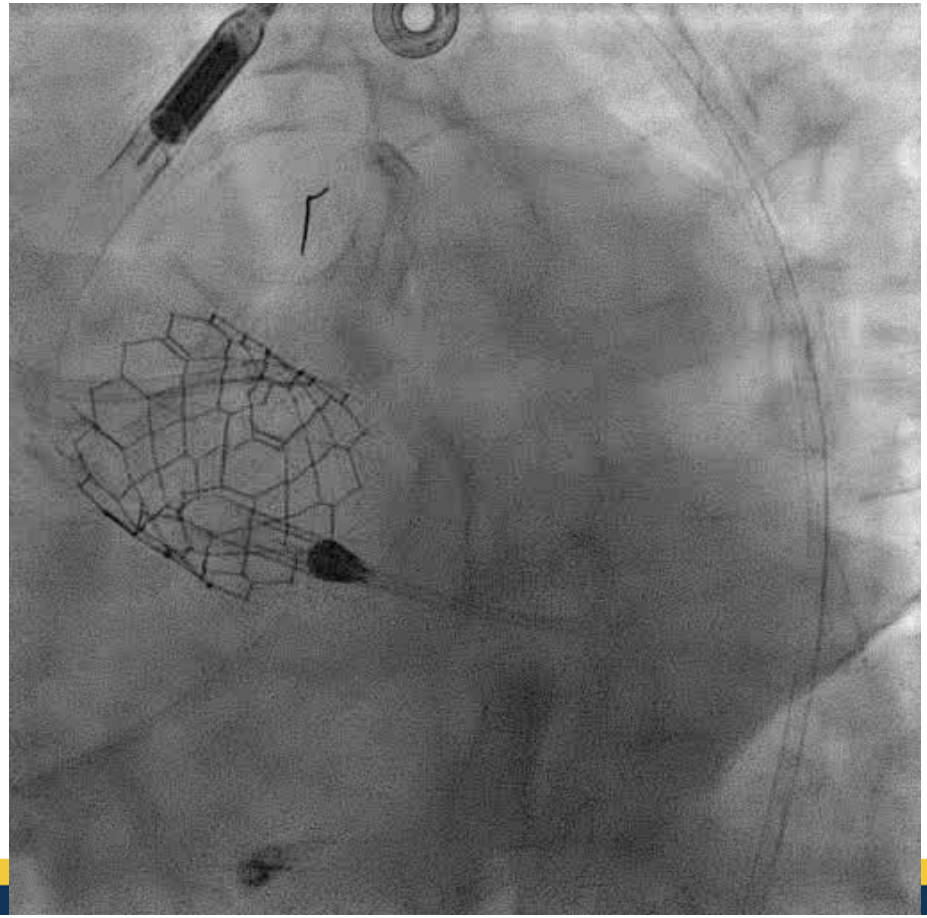

CSI LAD and post CSI angio w/contrast

CentraCare™

Wire moved to LCx for CSI, and Balloon

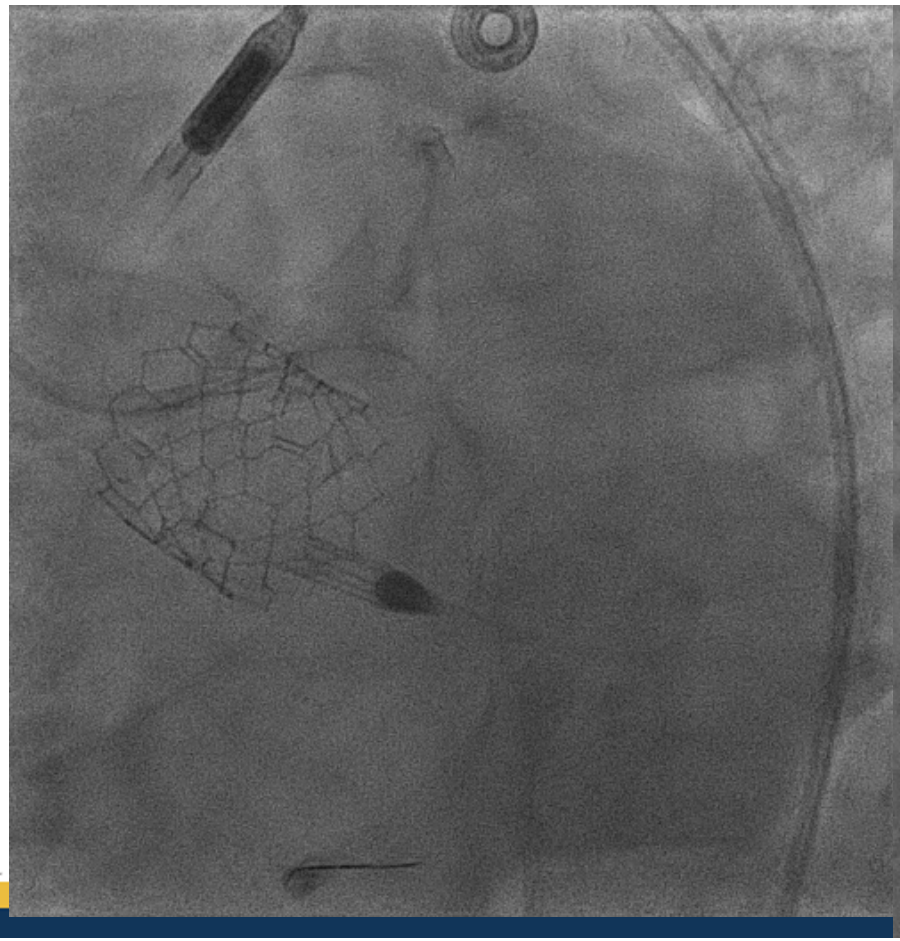

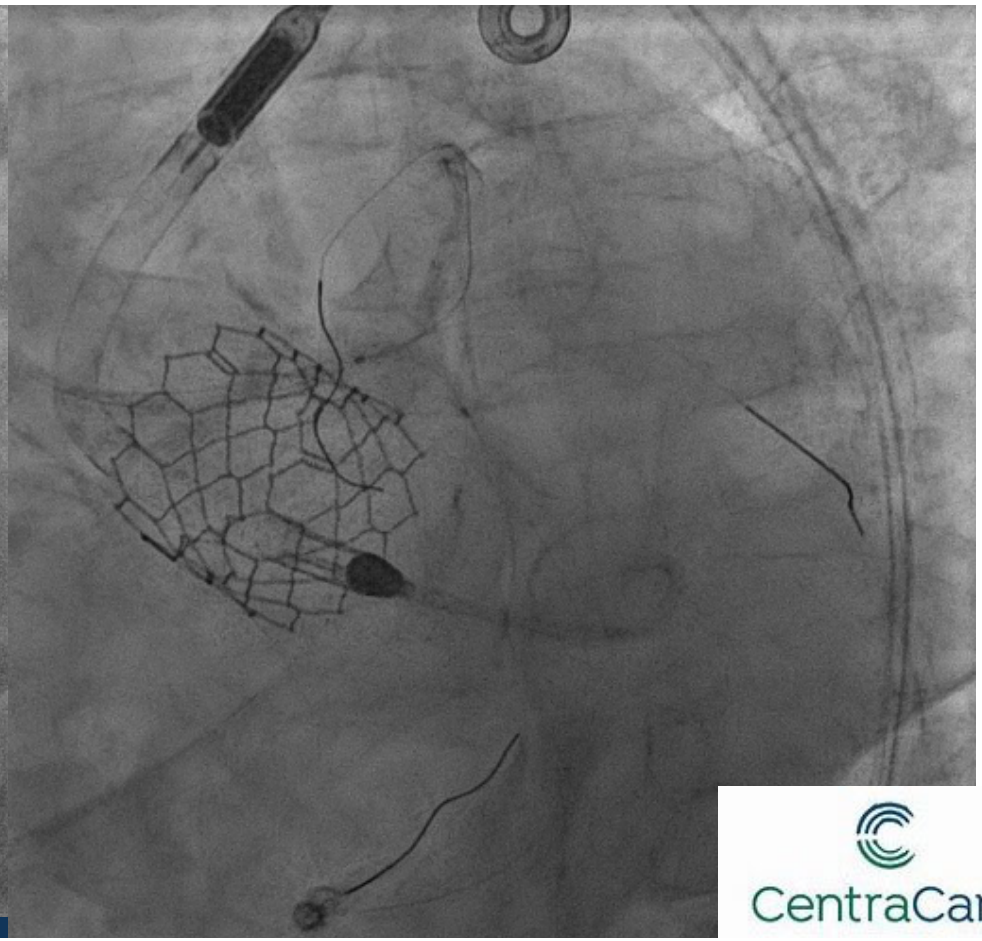

CAMP PCI
Coronary Artery & Myocardial Protected

CentraCare™

NC Balloon LAD and LCx

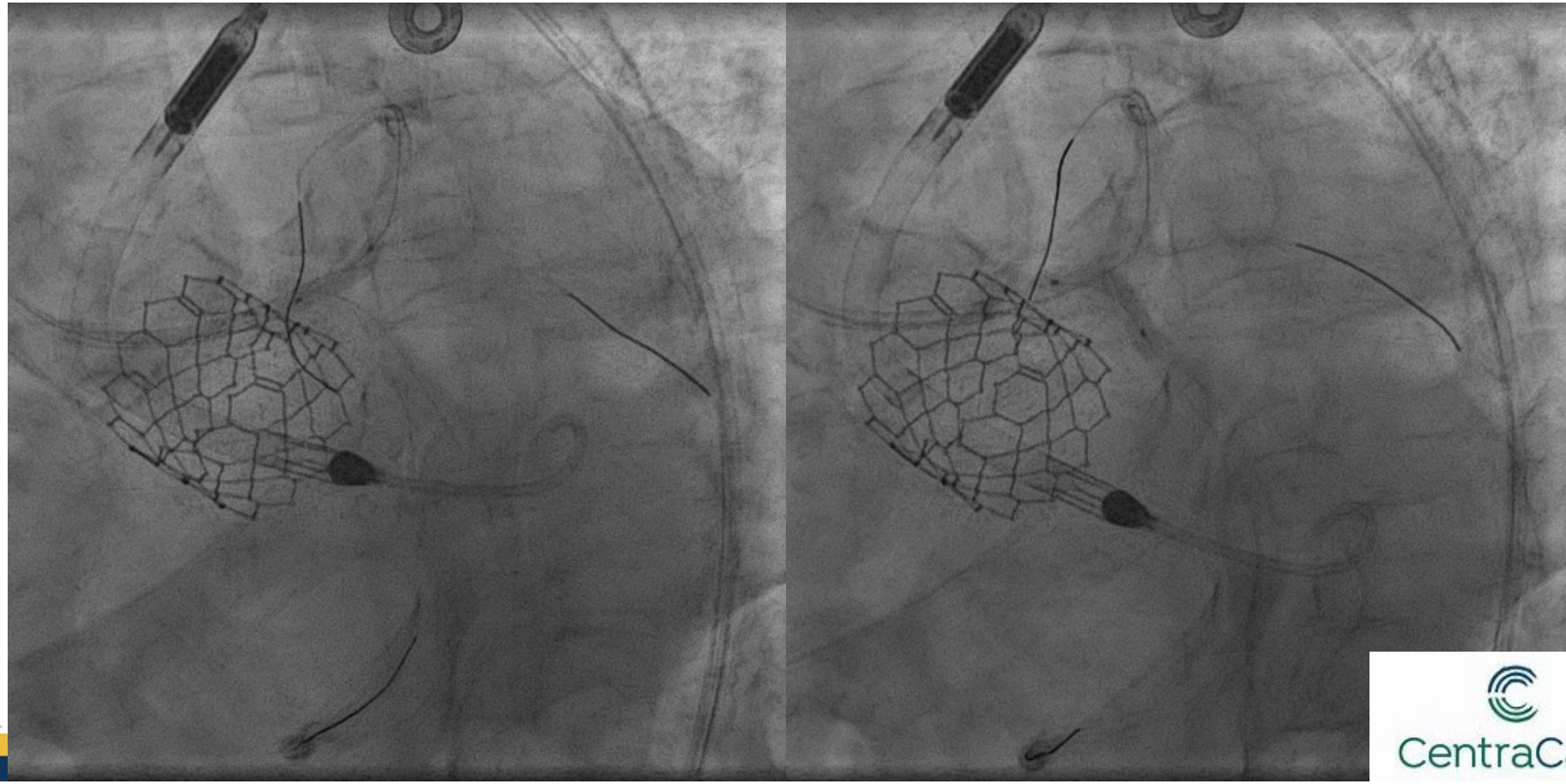

Stent mid LCx with Contrast, and LM-LCx

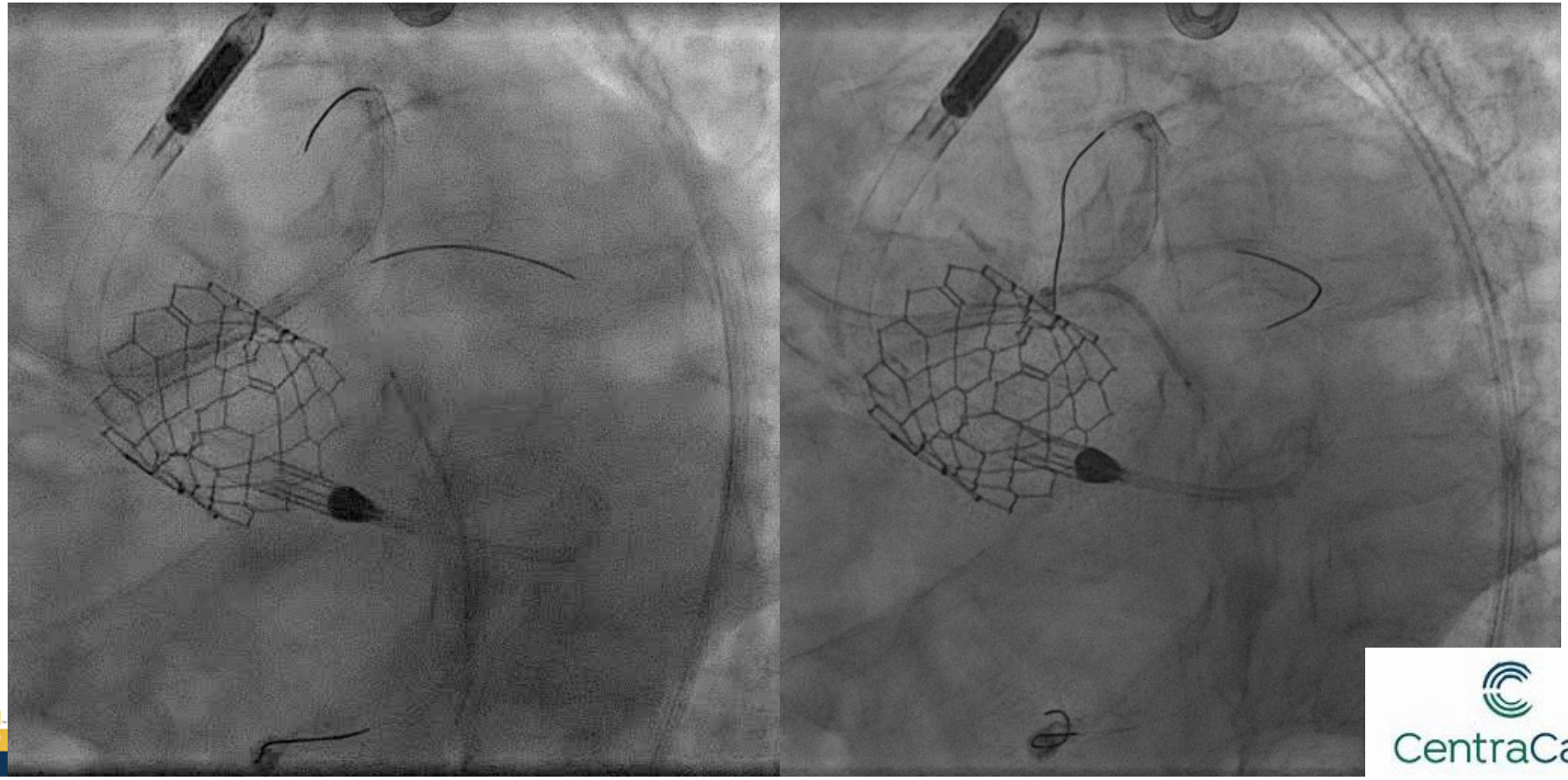

Balloon across LM-LCx stent and Coulotte LAD

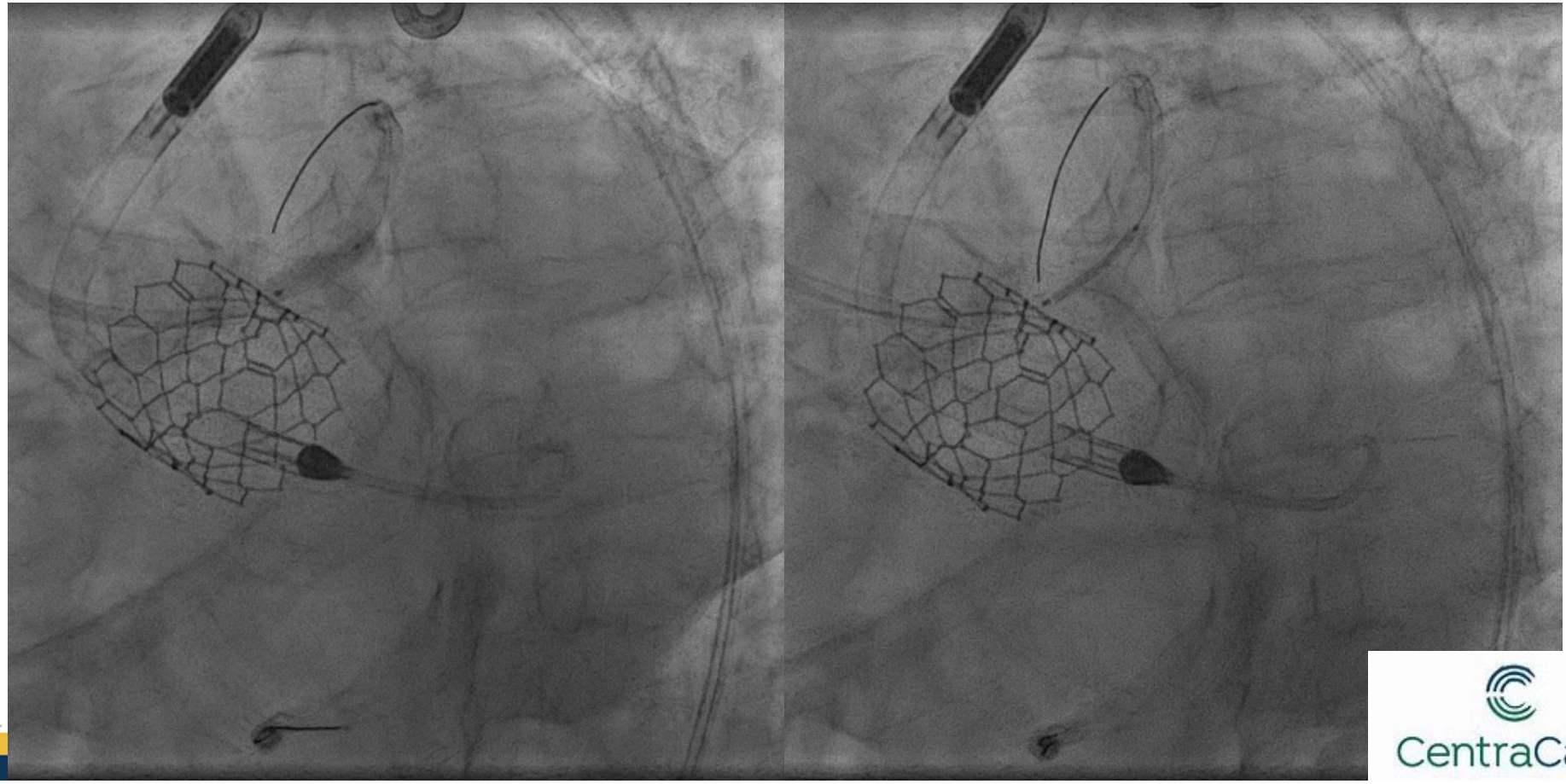

CAMP PCI
Coronary Artery & Myocardial Protected

CentraCare™

Kiss and Final

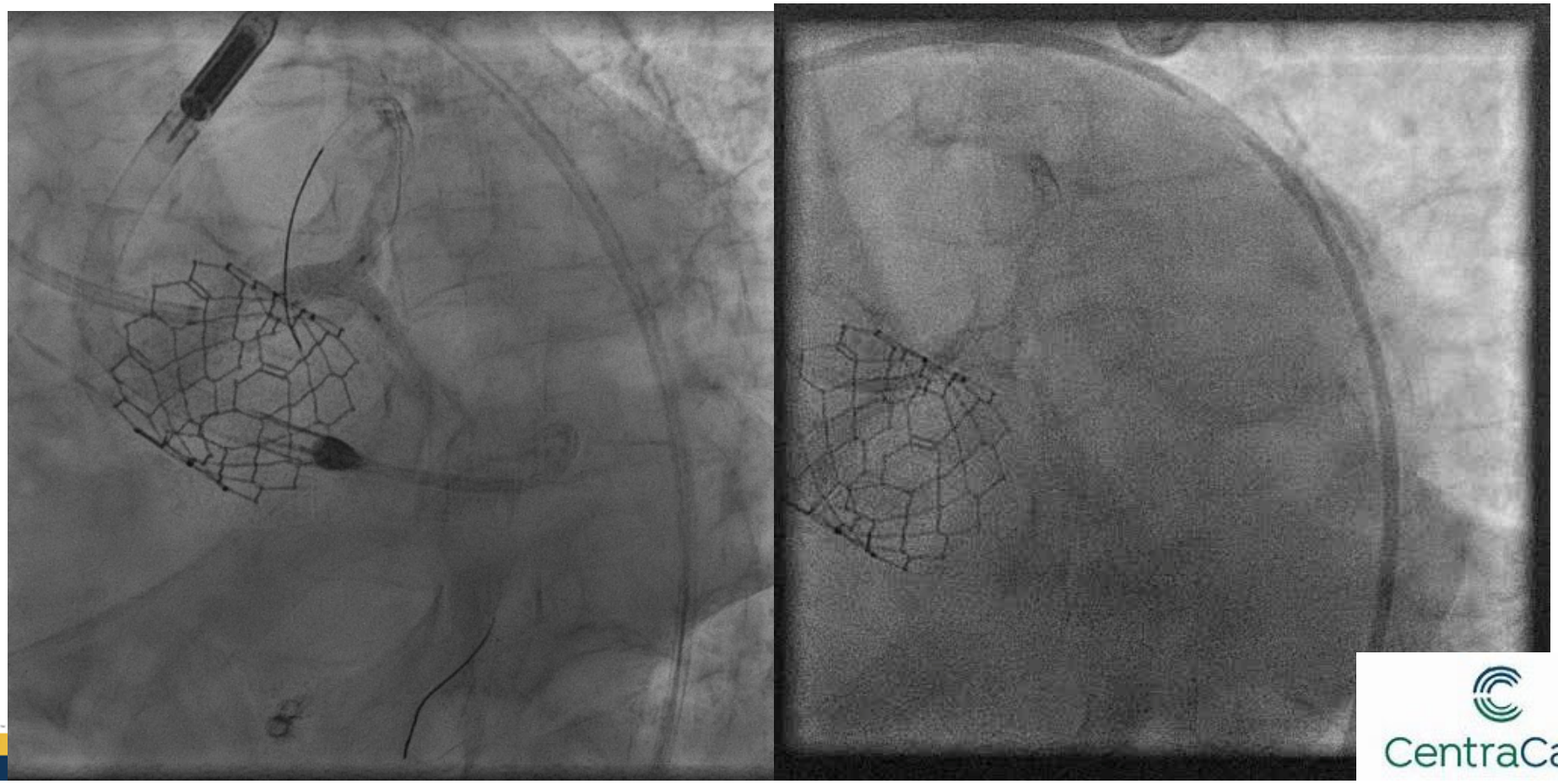

Pre

Post Closure

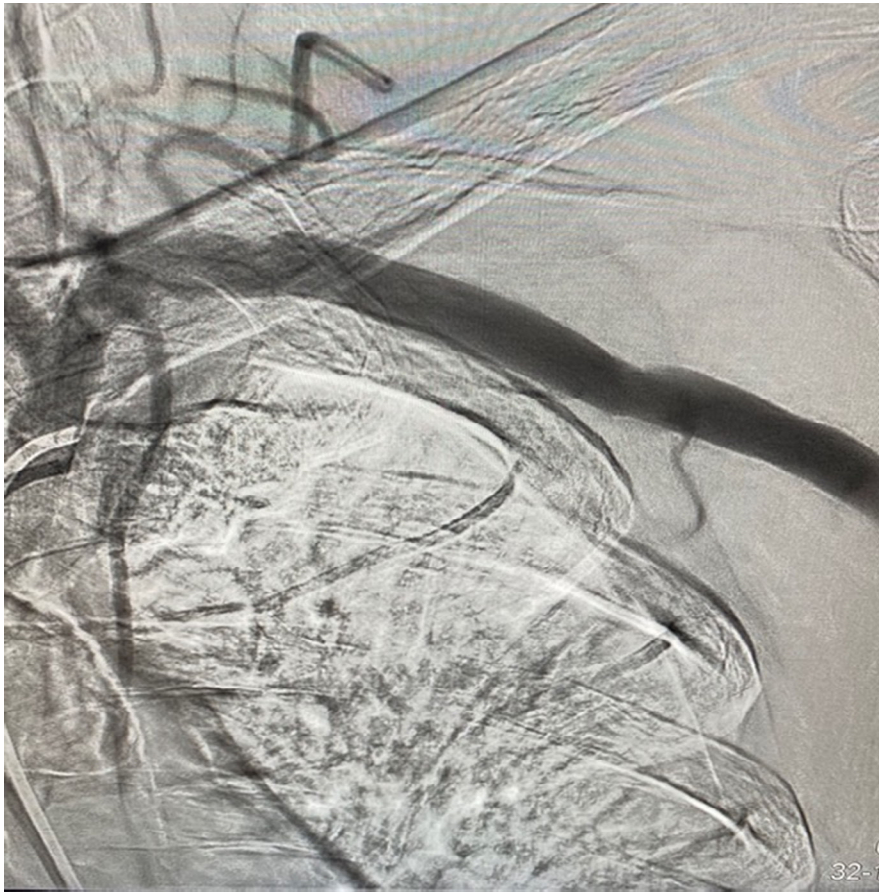

Patient Follow-Up

- Total Contrast 20cc
- Discharged on POD #1
- PreOp Cr 3.37
- POD #1 Cr 3.05
- POD #7 Cr 3.21
- Preop CCS Class IV (>10 SL nitro/day)
- Postop CCS Class 0 (No chest pain)

Conclusions

- Coronary calcium is under-appreciated and undertreated
- When in doubt use intra-coronary imaging (OCT > IVUS) (Dr. Ali next)
- Coronary calcium = higher MACE rates and worse long-term PCI outcomes, especially in low EF pts- be prepared- consider support!
- if severe Ca, severe tortuosity, or long lesions- atherectomy device choice, wire position, and technique matters!!!
- Consider development of a vessel preparation algorithm (Dr. Wollmuth)

THANK YOU

BLūOx

OPENING DECEMBER 7th